

Can subcutaneous treprostinil be an alternative for treating pulmonary hypertension in patients with systemic sclerosis-related interstitial lung disease?

Duarte AC^{1*}, Alegria S², Vinagre F¹, Ferreira F², Cordeiro A¹

¹ Serviço de Reumatologia, Hospital Garcia de Orta, Almada, Portugal

² Unidade de Hipertensão Pulmonar, Serviço de Cardiologia, Hospital Garcia de Orta, Almada, Portugal

* ORCID: 0000-0001-6128-2425

Correspondence to

Ana Catarina Duarte

E-mail: catarinaduarte89@gmail.com

Submitted: 30/11/2023

Accepted: 06/02/2024

This article has been accepted for publication and undergone full peer review but has not been through the copyediting, typesetting, pagination and proofreading process which may lead to differences between this version and the Version of Record. Please cite this article as an 'Accepted Article'

© 2024 Portuguese Society of Rheumatology

This article is protected by copyright. All rights reserved.

Dear Editor,

Pulmonary hypertension (PH) is one of the most feared complications of systemic sclerosis (SSc)¹. It is defined by mean pulmonary arterial pressure (mPAP) > 20mmHg at rest, during right heart catheterization (RHC)². Five PH groups have been described² and all can occur in SSc¹. There are specific drugs approved for PH group I - pulmonary arterial hypertension (PAH) and patients frequently need a combination therapy^{2,3}. The use of vasodilators is controversial in PH group III and not routinely recommended in patients with non-severe PH². However, SSc-PH- interstitial lung disease (ILD) has a poorer survival compared with SSc-PAH⁴ and an adequate screening strategy and prompt referral to a PH centre are crucial.

We report the case of a 45-year-old female, born in São Tomé and Príncipe, diagnosed with SSc-myositis overlap syndrome. She has documented lung involvement (ILD with fibrotic nonspecific interstitial/organizing pneumonia pattern; Figure 1), vascular involvement (Raynaud's phenomenon complicated with digital ulcers treated with intravenous iloprost), limited cutaneous involvement, upper gastrointestinal tract involvement and musculoskeletal involvement (oligoarthritis and proximal myositis). For ILD she was initially treated with intravenous cyclophosphamide (1g, monthly, 6 months) followed by mycophenolate mofetil (MMF) 2g/day, with lung disease stabilization (Table I). As arthritis persisted, rituximab (2x1g, 2 weeks apart) was added, although it had to be stopped after the fourth administration due to infusion reaction. The patient was then kept under MMF 2g/day, hydroxychloroquine 200mg/day and prednisolone 5mg/day.

Five months later she reported worsening dyspnea, with > 10% decrease in forced vital capacity and imaging documentation of ILD progression. The patient was retreated with intravenous cyclophosphamide (750mg, monthly for 3 months, which was interrupted due to SARS-CoV2-related constrains and resumed 4 months later for another 6 months). She initially reported symptomatic improvement, but after the sixth cyclophosphamide administration she was admitted into hospital with right heart failure symptoms. Chest computed tomography showed stable ILD and lung scintigraphy excluded pulmonary embolism. Her echocardiogram had an estimated PSAP of 73-78 mmHg, signs of right ventricle overload and mild pericardial effusion. She performed RHC compatible with pre-capillary PH (mPAP 45mmHg, pulmonary arterial wedge pressure [PAWP] 8mmHg, pulmonary vascular resistance [PVR] 16.82 WU). Despite known ILD, due to several high-risk criteria (WHO-FC III/IV, NTproBNP 4575 ng/L, right atrial

pressure [RAP] 21 mmHg, cardiac index [CI] 1.39 L/min/m², SvO₂ 50%), the decision was to start sequential combination therapy including parenteric prostanoid. The patient started sildenafil 25mg tid, with dose titration according to tolerability. Subcutaneous treprostinil was associated one month later (progressive titration up to 21 ng/kg/min) and bosentan 62.5mg bid was added four months later. The patient reported progressive symptomatic improvement with the last RHC compatible with pre and pos-capillary PH, without any high-risk criteria. Chest computed tomography after 2 years of pulmonary arterial vasodilators and under MMF 2g/day showed stable ILD.

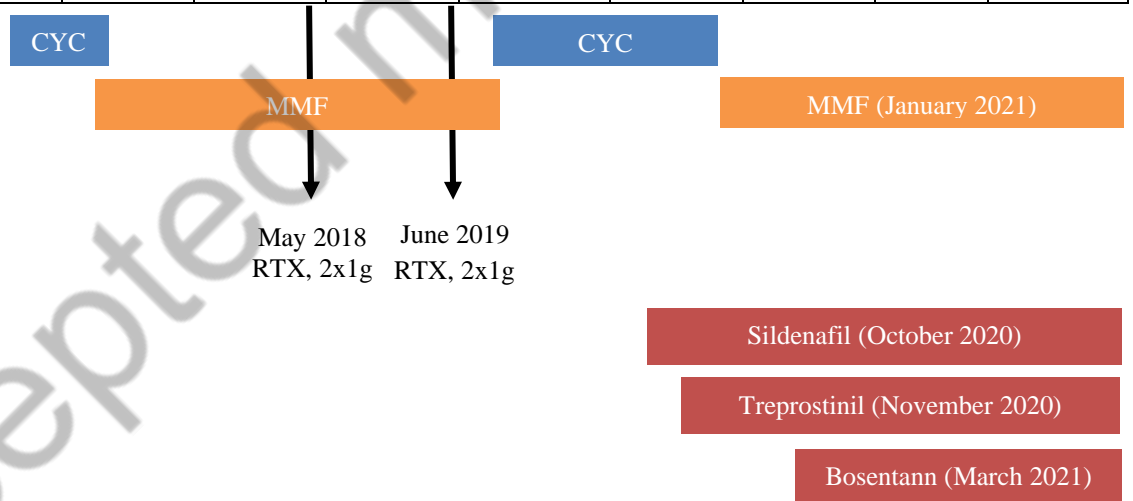
Previous studies on the use of PAH therapies in patients with idiopathic interstitial pneumonia-associated PH have been discouraging^{5,6} and associated with a potential worsening of ILD⁶, which in part may explain why, even with a suggestive echocardiogram, not all ILD patients performed RHC. More recently, INCREASE trial (including patients with connective tissue disease-ILD) demonstrated that inhaled treprostinil can significantly improve exercise capacity, decrease NT-proBNP and reduce the risk of clinical worsening and the number of exacerbations, when compared with placebo^{7,8}.

Treprostinil can now be considered in patients with PH associated ILD² and its continuous subcutaneous formulation ensures therapeutic adherence in patients who are often polymedicated. The authors truly believe that by sharing their experience they can reinforce that a new window of opportunity is being opened for diagnosis, but above all for treatment of PH in SSc-ILD patients.

Tables and Figures

Table I – Clinical evolution and complementary exams over time, according to ongoing treatment

	March 2015	March 2016	April 2017	February 2018	October 2018	November 2019	October 2020	February 2021	January 2022	February 2023
WHO-FC	II	II	II		II	III	III/IV	III	III	II/III
FVC (%)	32.8	48.9	46.5	41.2	43.9	34	-	-	-	40
DLCO (%)	-	32	33	19.1	25.1	-	-	-	-	25
NTproBNP (ng/L)	-	58	63	33	283	1717	4575	505	721	182
PSAP (mmHg)	-	32	32	33	33	58	73-78	62	84	77
mPAP (mmHg)	-	-	-	-	-	-	45	50	-	48
RAP (mmHg)	-	-	-	-	-	-	22	9	-	10
CI (L/min/m ²)	-	-	-	-	-	-	1.39	1.9	-	2.34
SvO ₂	-	-	-	-	-	-	50	58	-	79
6MWD (distance)	-	-	-	-	-	310	200	-	-	250



WHO-FC – World Health Organization – functional class; FVC – forced vital capacity; DLCO - diffusing capacity for carbon monoxide; NT-proBNP - N-terminal pro-B-type natriuretic peptide; PSAP – pulmonary artery systolic pressure; mPAP – mean pulmonary artery pressure; RAP – right atrial pressure; CI – cardiac index; SvO₂ – mixed venous oxygen saturation; 6MWD – 6-minute walking distance; CYC- cyclophosphamide; MMF – mycophenolate mofetil; RTX - rituximab

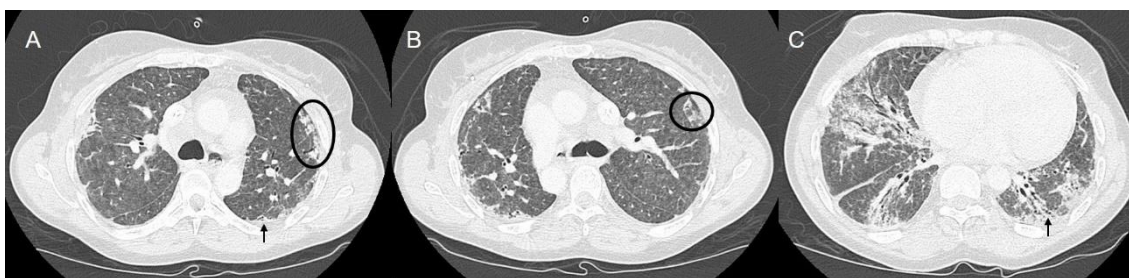


Figure 1 - Chest computed tomography showing ground glass opacities, with subpleural sparing (circle) and traction bronchiectasis (arrow). At lower lobes there are foci of patchy consolidation with air bronchogram (C).

References

1. Haque A, Kiely DG, Kovacs G, et al. Pulmonary hypertension phenotypes in patients with systemic sclerosis. *Eur Respir Rev* 2021;30:210053.
2. Humbert M, Kovacs G, Hoeper MM, et al. 2022 ESC/ERS Guidelines for the diagnosis and treatment of pulmonary hypertension. *Eur Respir J* 2023;61:2200879.
3. Smukowska-Gorynia A, Gościński W, Woźniak P, et al. Recent Advances in the Treatment of Pulmonary Arterial Hypertension Associated with Connective Tissue Diseases. *Pharmaceuticals (Basel)* 2023;16:1252.
4. Lefèvre G, Dauchet L, Hachulla E, et al. Survival and prognostic factors in systemic sclerosis-associated pulmonary hypertension: a systematic review and meta-analysis. *Arthritis Rheum* 2013;65:2412-2423.
5. Corte TJ, Keir GJ, Dimopoulos K, et al. Bosentan in pulmonary hypertension associated with fibrotic idiopathic interstitial pneumonia. *Am J Respir Crit Care Med* 2014;190:208-217.
6. Nathan SD, Behr J, Collard HR, et al. Riociguat for idiopathic interstitial pneumonia-associated pulmonary hypertension (RISE-IIP): a randomised, placebo-controlled phase 2b study. *Lancet Respir Med* 2019;7:780-790.
7. Waxman A, Restrepo-Jaramillo R, Thenappan T, et al. Inhaled Treprostinil in Pulmonary Hypertension Due to Interstitial Lung Disease. *N Engl J Med* 2021;384:325-334.
8. Waxman A, Restrepo-Jaramillo R, Thenappan T, et al. Long-term inhaled treprostinil for pulmonary hypertension due to interstitial lung disease: INCREASE open-label extension study. *Eur Respir J* 2023;61:2202414.