

IMAGES IN RHEUMATOLOGY

# Butterfly Vertebra: the mimicker of vertebral fragility fractures

Bento da Silva A<sup>1\*</sup>, Lourenço MH<sup>2</sup>, Gonçalves MJ<sup>3</sup>, Branco JC<sup>4</sup>, Costa M<sup>5</sup>

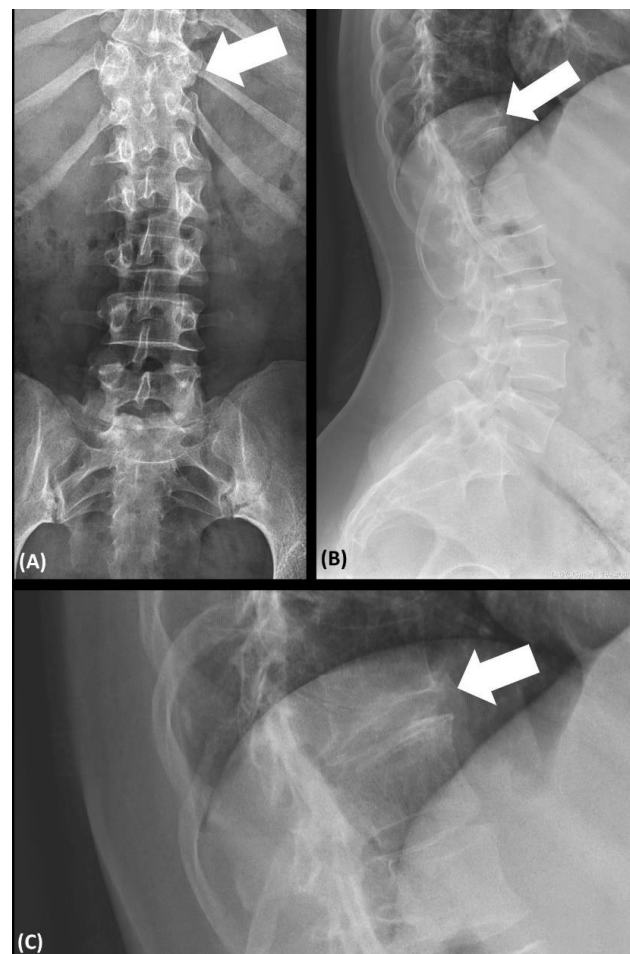
**BACKGROUND**

Low back pain (LBP) is a common complaint in the general population and the most frequent rheumatic musculoskeletal disease in Portugal (prevalence of 26.4%, according to the EpiReumaPt study)<sup>1</sup>. However, identifying the cause of LBP can be challenging, consequence of its extensive differential diagnosis. Vertebral fragility fractures can be responsible for 0.7% to 4.5% of LBP cases in the primary care setting<sup>2</sup>. They can be easily recognized by conventional radiographs of the spine, but awareness for potential mimickers is essential, especially in younger patients.

**CASE REPORT**

A 41-year-old pre-menopausal woman was referred to the rheumatologist due to LBP of insidious onset and gradual worsening lasting more than one year, without other symptoms or history of previous trauma. She had no relevant medical or drug history. She was a non-smoker and maintained a healthy diet and regular physical activity. Besides a slightly high body mass index (27.7Kg/m<sup>2</sup>), the physical exam was unremarkable. The patient performed a spine X-ray that showed a sinking of the vertebral plate of the 11<sup>th</sup> dorsal vertebra (D11), suggesting a fragility fracture (Figure 1). Her blood work revealed a slightly raised parathormone (75.5pg/mL) and vitamin D deficiency (47.5nmol/L), that resolved after vitamin D supplementation, without other abnormalities (including calcium, phosphorus, alkaline phosphatase and thyroid function). Dual-energy X-ray absorptiometry (DXA) suggested a trabecular osteoporosis (spinal T-score of -3.2; femoral neck T-score of -0.6). Thus, she was first diagnosed as having severe osteoporosis with a vertebral fracture and started alendronate 70mg/week. After consulting an attending neurosurgeon, she performed a computed

tomography (CT) scan of the thoracolumbar spine (Figure 2) to better characterize the suspected vertebral fracture. The CT excluded the presence of fractures and showed instead a vertebral deformity at D11 called *butterfly vertebra*, giving the vertebra a wedge morphology with greater posterior base, mimicking a vertebral fracture. After 6 months, the pain had gradually improved, without need of further treatment. Due to DXA results consistent with a diagnosis of osteoporosis, she maintained alendronate once weekly.



**Figure 1.** Conventional radiographs of the thoracolumbar spine in antero-posterior (A) and lateral (B and C) views, showing D11 with a wedge deformity (arrows).

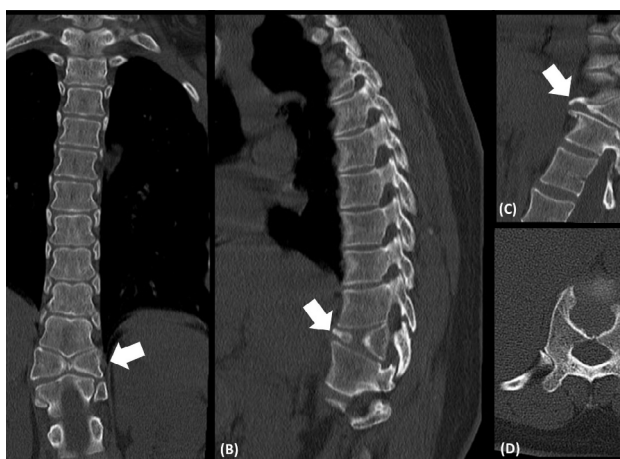
<sup>1</sup> Rheumatology, Centro Hospitalar de Lisboa Ocidental EPE  
\*ORCID: 0000-0002-8590-8119

Submitted: 24/05/2023

Accepted: 02/08/2023

Correspondence to: Ana Bento

E-mail: adbentosilva@gmail.com



**Figure 2.** Computed tomography scan of the thoracolumbar spine in coronal (A), sagittal (B and C) and axial (D) views, showing a butterfly vertebra at the level of D11 (arrows).

## DISCUSSION

Butterfly vertebra is a rare spinal congenital anomaly, first described by Rokitsansky in 1850 in a 55-year-old man<sup>3</sup>. It results from a failure of fusion of the two lateral chondrification centers of vertebrae between the third and sixth week of gestation, giving the vertebra a butterfly-like appearance<sup>3</sup>. In most cases (61%) a single vertebra is affected, mainly in the thoracolumbar spine<sup>3</sup>. There are reported associations with other syndromic diseases (Alagille, Crouzon or Pfeiffer syndromes) or spinal anomalies (kyphoscoliosis or supernumerary

vertebrae), especially if multiple vertebral involvement, but can occur in isolation in 44% of cases<sup>3,4,5</sup>. It has a wide differential diagnosis, with 10% of cases being misdiagnosed as fragility fractures, which assumes a greater relevance in patients with LBP, the most common presenting feature, although usually asymptomatic<sup>3</sup>. Butterfly vertebra is a rare congenital spinal anomaly that may mimic an osteoporotic fracture and awareness for this condition is essential to avoid misdiagnosis and overtreatment. Moreover, given the association with other syndromic diseases, its recognition is crucial to ensure patients are treated accordingly.

## REFERENCES

1. Branco JC, Rodrigues AM, Gouveia N, Eusébio M, Ramiro S, Machado PM, Pereira da Costa L, Mourão AF, Silva I, Laires P, Sepriano A, Araújo F, Gonçalves S, Coelho PS, Tavares V, Cerol J, Mendes JM, Carmona L, Canhã H, on behalf of the EpiReumaPt study group. Prevalence of rheumatic and musculoskeletal diseases and their impact on health-related quality of life, physical function and mental health in Portugal: results from EpiReumaPt – a national health survey. *RMD open* 2016; 2(1): e000166.
2. Williams C M, Henschke N, Maher CG, van Tulder MW, Koes BW, Macaskill P, Irwig L. Red flags to screen for vertebral fracture in patients presenting with low-back pain. *Cochrane Database of Systematic Reviews* 2013; (1).
3. Katsuura Y, Kim HJ. Butterfly vertebrae: a systematic review of the literature and analysis. *Global Spine Journal* 2019; 9(6): 666-679.
4. Giraldo WAS, Rivera JIG, Díaz MV. Vértebra en mariposa. *Reumatología Clínica* 2015; 11(1): 52-53.
5. Kapetanakis S, Giannopoulou E, Nastoulis E, Demetriou T. Butterfly vertebra. A case report and a short review of the literature. *Folia morfológica* 2016; 75(1): 117-121.