

## Urticiform lupus-like reaction induced by adalimumab: a rare adverse effect

Lourenço MH<sup>1</sup>, Silva AB<sup>1</sup>, Silva I<sup>1</sup>, Branco JC<sup>1</sup>

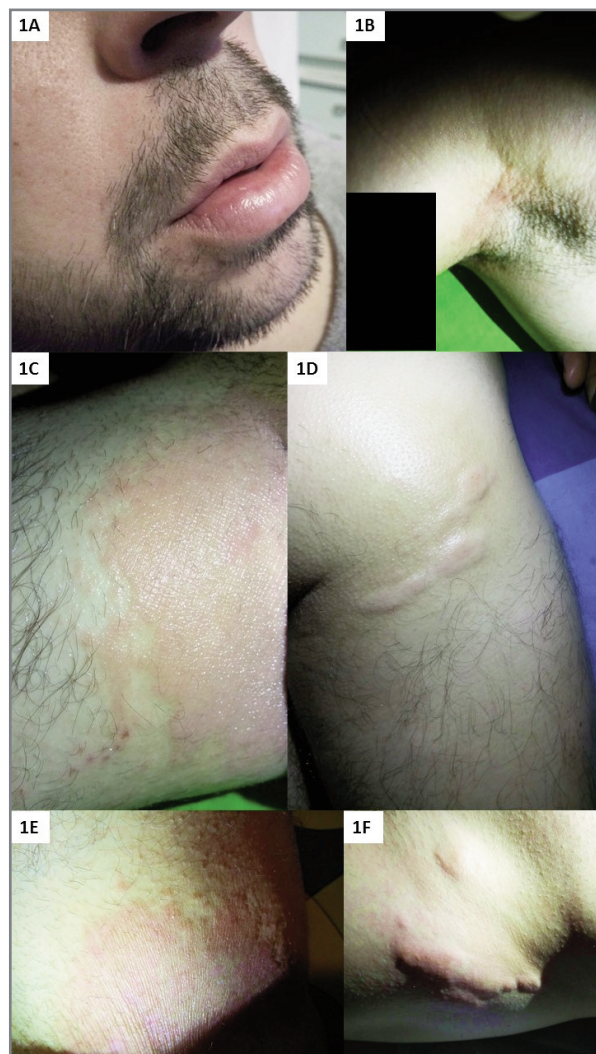
ACTA REUMATOL PORT. 2021;46:368-369

To the editor,

Adalimumab is a fully human recombinant monoclonal antibody [immunoglobulin (Ig) G1] anti-tumor necrosis factor alpha (anti-TNF $\alpha$ ). It is approved for the treatment of rheumatoid arthritis, spondylarthritis, juvenile idiopathic arthritis, psoriasis, hidradenitis suppurativa, anterior uveitis, and inflammatory bowel disease<sup>1,2</sup>. The most frequently reported adverse effects are infections and injection-site reactions. Other skin reactions are described in ~1% of reports and include anaphylactic reactions, rash, fixed eruption and urticaria<sup>3</sup>. Drug-induced lupus is a subtype of lupus associated with prolonged exposure to some medications, the most common being hydralazine, procainamide and anti-TNF $\alpha$ <sup>4</sup>. We report a case of a patient diagnosed with psoriatic arthritis under treatment with adalimumab that developed urticaria associated with high titers of both antinuclear antibodies (ANA) (nuclear homogeneous pattern) and anti-double stranded DNA antibodies (anti-dsDNA). After exclusion of other causes, it was concluded to be secondary to the biological agent.

A 43-year-old man, with no other relevant medical history, was followed in our outpatient rheumatology clinic since 2014 with the diagnosis of psoriatic arthritis (asymmetric nonerosive polyarticular and enthesopathic involvement) and skin psoriasis. The initial treatment based on prednisolone 10mg/day with progressive dose reduction to 2.5mg/day and subcutaneous methotrexate 25mg/week, was switched to corticosteroids and leflunomide 20mg/day because of gastrointestinal side effects. In July 2019, adalimumab (Humira®) 40mg biweekly subcutaneous injection was added as the patient maintained articular and enthesopathic inflammatory activity [*minimal disease activity* (MDA) < 5], reaching clinical remission. In March 2020, the patient experienced multiple maculopapular, erythematous, evanescent, and migratory plaques, variable in size and shape and severely pruriginous, although painless. They were mainly located in hair scalp, upper

limbs and intertrigo regions and accompanied by angioedema of lips and face (without hoarseness or shortness of breath) (Figure 1). The plaques appeared 2-3



**FIGURE 1.** Urticiform reaction presented by the patient, with multiple maculopapular, erythematous, evanescent plaques, with different sizes and shapes, in various regions of the body (1A – labial angioedema; 1B – right axilla; 1C – right inner thigh; 1D – right posterior thigh; 1E – left anterior thigh; 1F – posterior area of the right upper arm)

1. Serviço de Reumatologia, Hospital de Egas Moniz

times per week, each one lasting for 24 hours and resolving without scarring. No other symptoms were reported. Laboratory investigation revealed hepatic cytolysis without cholestasis (aspartate aminotransferase 49 U/L, alanine aminotransferase 60 U/L; lactate dehydrogenase 349 U/L) and strongly positive ANA with a homogeneous nuclear pattern (no previous measurement available) and positive anti-dsDNA. Subsequent immunological investigation was negative (complement fraction C3 and C4, extractable nuclear antibodies, antineutrophil cytoplasmic antibodies, anti-histone antibodies). The levels of immunoglobulins (namely IgE), C1q component of the complement and tryptase were normal. Serum creatinine and urinalysis revealed no changes. Adalimumab was then discontinued, with a significant reduction in the number and frequency of the skin eruptions, and antihistamine medications on-demand were started; corticosteroids were not needed for this reason. Skin biopsy was not performed as the rash completely resolved. It was then assumed to be a lupus-like urticaria reaction induced by adalimumab; the decision was to switch to secukinumab, and the patient kept remission of symptoms (MDA>5) No more urticaria episodes were observed during the follow-up period.

Allergic reactions to adalimumab, as urticaria and angioedema, are rare adverse events considering that the drug is mainly an IgG1 with a human sequence. However, a slight degree of immunogenicity may exist. To assume a diagnosis of drug-induced lupus, three conditions should be met: a time-cause relationship, a serological criterion and a clinical one<sup>5,6</sup>. Despite the signs and symptoms observed being exclusively skin manifestations and hypersensitivity reactions, a causality relationship was observed between the beginning of the rash and the laboratory changes and the resolution of the signs after discontinuing adalimumab. An urticariform lupus-like reaction induced by anti-TNF $\alpha$  is very rare, with an absence of similar cases described

in the literature. The therapeutical approach consisted of switching the biological drug to one with a different mechanism of action, discontinuing leflunomide, as it is rarely associated with skin reactions, and keeping antihistamine drugs on-demand<sup>7</sup>.

This case report describes an uncommon adverse event of the inhibitors of tumor necrosis factor and it constitutes a reminder of their pleomorphic presentation.

#### CORRESPONDENCE TO

Maria Helena Lourenço  
Serviço de Reumatologia, Hospital de Egas Moniz  
Rua da Junqueira 126  
1349-019 Lisboa  
E-mail: mariahelena.lourenco27@gmail.com

#### REFERENCES

1. Resumo das Características do Medicamento - Humira (European Medicines Agency). [https://www.ema.europa.eu/en/documents/product-information/humira-epar-product-information\\_pt.pdf](https://www.ema.europa.eu/en/documents/product-information/humira-epar-product-information_pt.pdf). Accessed in March 19th 2021.
2. Benucci M, Manfredi M, Testi S, Iorno ML, Valentini M, Soldaini F, et al. Spondylarthritis presenting with an allergic immediate systemic reaction to adalimumab in a woman: a case report. *J Med Case Rep* 2011; 5(1), 1-4. doi:10.1186/1752-1947-5-155.
3. George SJ, Anderson HL, Hsu S. Adalimumab-induced urticaria. *Dermatol Online J*, 2006; 12(2).
4. He Y, Sawalha AH. Drug-induced lupus erythematosus: an update on drugs and mechanisms. *Curr Opin Rheumatol.*, 2018; 30(5):490-497. doi:10.1097/BOR.0000000000000522.
5. Shovman O, Tamar S, Amital H, Watad A, Shoenfeld Y. Diverse patterns of anti-TNF- $\alpha$ -induced lupus: case series and review of the literature. *Clin Rheumatol*, 2018; 37(2):563-568. doi:10.1007/s10067-017-3884-2
6. Lomicová I, Suchý D, Pizinger K, Cetkovská P. A case of lupus-like syndrome in a patient receiving adalimumab and a brief review of the literature on drug-induced lupus erythematosus. *J Clin Pharm Ther*, 2017; 42(3):363-366. doi:10.1111/jcpt.12506.
7. Shastri V, Betkerur J, Kushalappa PA, Savita TG, Parthasarathi G. Severe cutaneous adverse drug reaction to leflunomide: a report of five cases. *Indian J Dermatol Venereol Leprol* 2006; 72(4):286-9. doi:10.4103/0378-6323.26725.