Shoulder giant schwannoma – a diagnosis to be considered in painless shoulder masses

Pinho R[1], Santana S[2], Farinha F[3], Cunha I[3], Barcelos A[3], Brenha J[1]

ACTA REUMATOL PORT. 2017;42:332-333

INTRODUCTION

Tumours formed from peripheral nerve sheaths are rare in the shoulder[1]. Benign tumours can be classified as traumatic neuromas, neurofibromas and schwannomas. There are also malignant tumours of peripheral nerve sheath cells[2]. Solitary neurofibromas and schwannomas cause similar signs and symptoms, with no distinctive pathognomonic clinical features between them[3]. They may present as an isolated mass of uncertain origin and evolution time. Despite its rarity, the unawareness of its existence and nature can lead to unnecessary surgery and a consequent risk of catastrophic iatrogenic loss of function[1-3].

CLINICAL CASE

We present the case of a 80-year-old female referred to an orthopaedic surgery clinic because of a large painless mass of the right shoulder (RS), with one year of evolution. There was no history of trauma, involvement of any other joint or systemic complaints.

On physical examination, a mobile mass, with elastic consistency and 9 cm of larger diameter, was palpated in the upper posterior region of the RS. There was no tenderness or functional limitation on exploration.

The ultrasound revealed "...with posterior localization in relation to the right shoulder, a liquid collection, measuring about 8,2x6,5x4,3cm". For better characterization, a computed tomography (CT) scan (Figure 1) and then a magnetic resonance imaging (MRI) (Figure 2) were requested.

Given the clinical suspicion of a giant synovial cyst

FIGURE 1. RS CT scan showing in the posterolateral face of the right shoulder, a bulky cystic formation, outlining some septation, with about 10.2x3.6cm and being located between the muscular plane of infra-spinous and teres minor and the deltoid, with nonspecific features.

the patient underwent complete surgical resection of the mass, which took place without any complications or functional impairment of the right upper limb. We used a Judet approach, working through the infraspinatus and teres minor interval, retracting teres minor inferiorly (avoiding injury to posterior branch of axillary nerve) and retracting infraspinatus superiorly (avoiding injury to suprascapular nerve and artery).

Macroscopically the surgical specimen was a mass

1. Serviço de Ortopedia e Traumatologia, Centro Hospitalar do Baixo Vouga, E.P.E.
2. USF Atlântico Norte, ACES Baixo Vouga
3. Serviço de Reumatologia, Centro Hospitalar do Baixo Vouga, E.P.E.

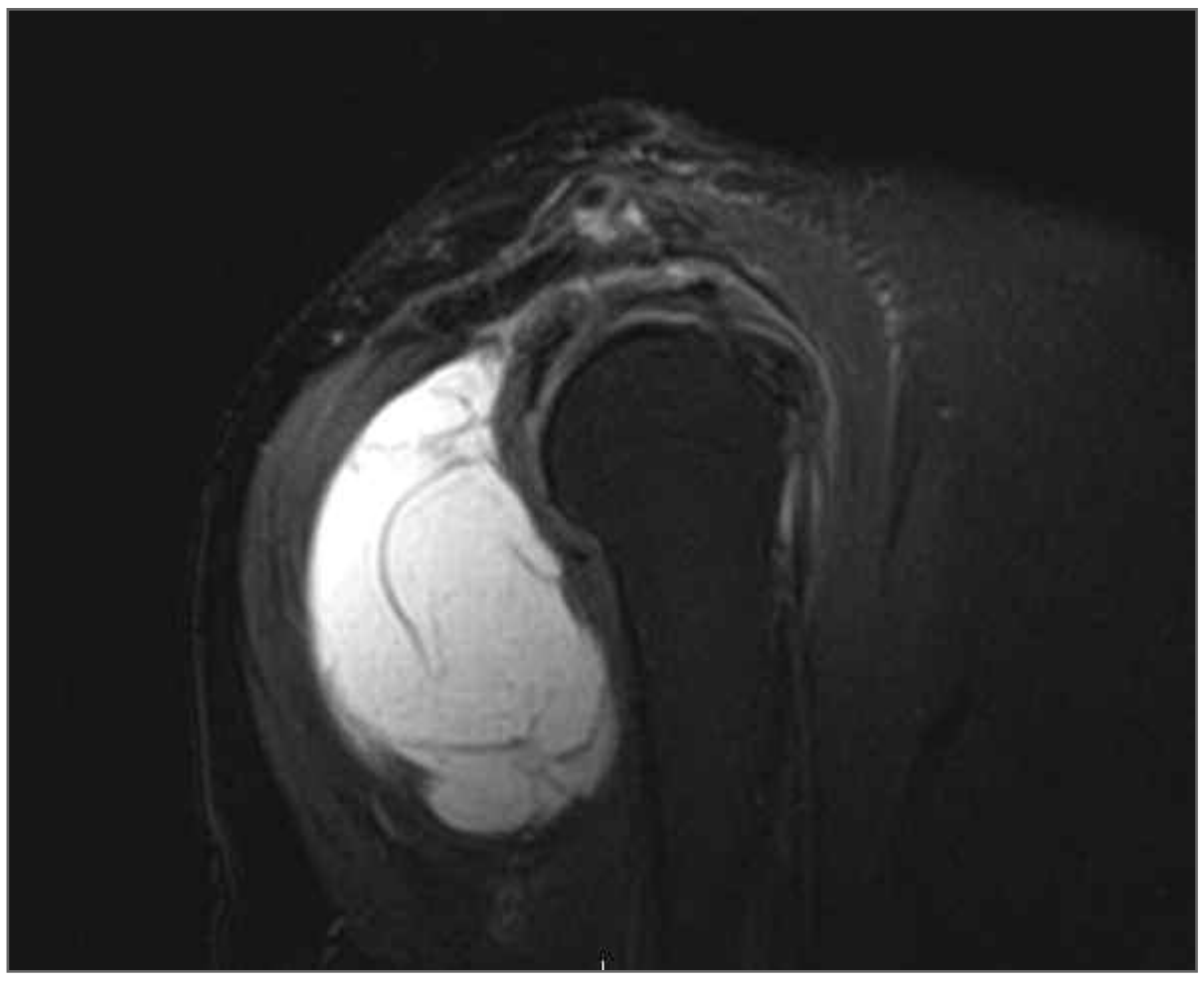

FIGURE 2. RS MRI showing, between the plan of the infra-spinous and teres minor muscles and the plan of the deltoid muscle, a complex mass lesion of cystic predominance, measuring approximately 100x93x50mm. This lesion had in the anterior region one solid area, with 70x47x27mm that suffered heterogeneous enhancement after contrast

FIGURE 3. Surgical resection: intraoperative image

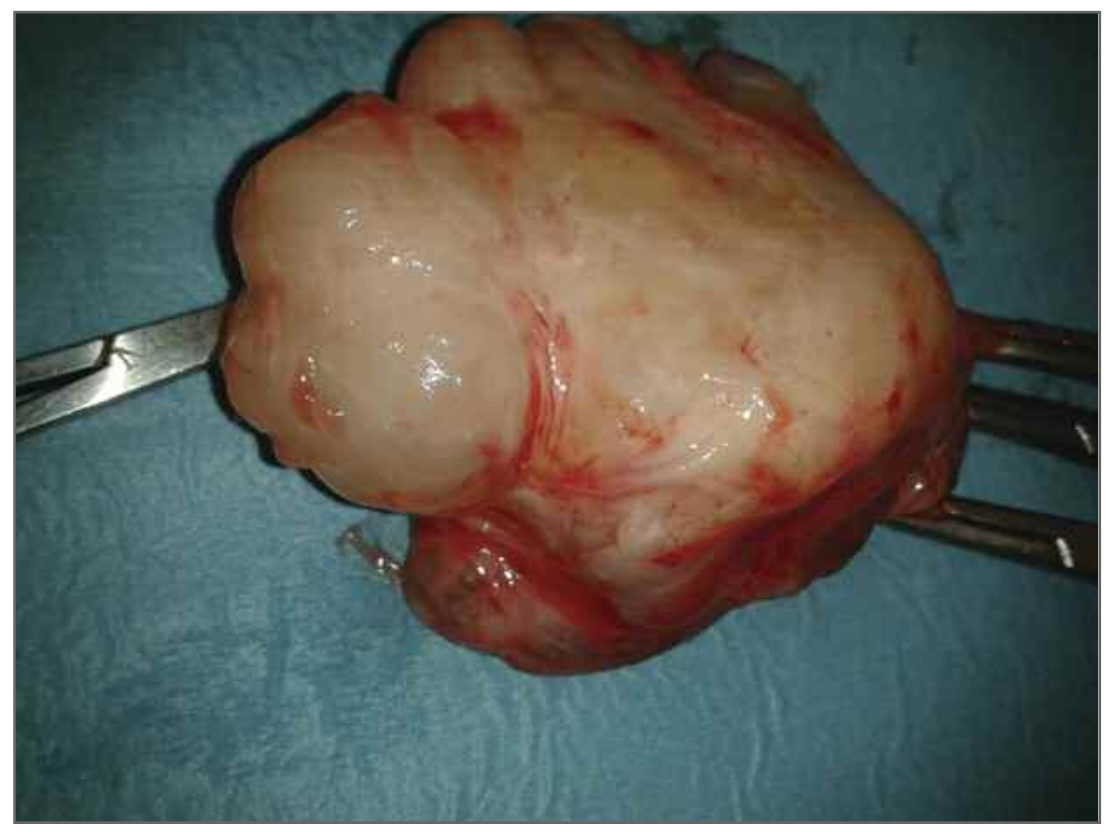

FIGURE 4. Specimen from surgical excision (solid part).

of soft consistency with 9x7x3,8 cm, mostly solid. There was also a cystic part with a membranous wall. Microscopic examination described a fusocellular pattern with myxoid stromae with a surrounding pseudocapsule, corresponding to a benign tumour of nerve sheaths, more specifically, a schwannoma.

Histological diagnosis turned out to be unexpected given the dimensions and imagiological characteristics of the lesion and the low incidence of isolated tumours of peripheral nerve sheaths. The patient recovered well and was discharged. At 3 years follow-up, no functional impairment or signal of recurrence is present.

These benign tumours present usually as a slow growth mass, where pain and neurological deficits are uncommon[1]. Among the many complementary tests available, MRI is the gold standard[1-3].

Still, the diagnosis is made preoperatively only in a minority of cases[1,2]. The risk of nerve injury during surgery exists and is higher in neurofibromas because of the closer involvement with the nerve fibers[1,3].

We emphasize the need to consider this rare clinical entity in the differential diagnosis of slow evolution tumourations of the shoulder, in order to avoid unnecessary surgery and to minimize the risk of iatrogenic injury of the involved nerve[1,2].

CORRESPONDENCE TO
Romeu Pinho
Rua Dr João Rocha, nº 13
E-mail: romeupinho@gmail.com

REFERENCES

1. Hung YW, Tse WL, Cheng HS, Ho PC. Surgical excision for challenging upper limb nerve sheat tumours: a single centre retrospective review of treatment results. Hong Kong Med J 2010;16:287-291.
2. Kehoe NJ, Reid RP, Semple JC. Solitary benign peripheral-nerve tumours. J Bone Joint Surg Br 1995;77-B:497-500.
3. Canale ST, Beaty JH. Campbells Operative Orthopaedics. Philadelphia: Mosby, 2008:940-942.