

The use of the color Doppler ultrasonography in the diagnosis and monitoring of an atypical case of giant-cell arteritis

Martins N¹, Polido-Pereira J², Rodrigues AM³, Soares F⁴, Batista P⁴, Pereira da Silva JA²

ACTA REUMATOL PORT. 2016;41:165-166

Giant cell arteritis (GCA) is a large vessels vasculitis that is typically characterised by headaches, scalp tenderness, jaw claudication and visual disturbances. Temporal arteries color Doppler ultrasonography (CDUS) is a sensitive and non-invasive image technique used in the diagnosis of this disease¹. The typical changes are inflammatory oedema of the vessel wall (halo sign), as well as stenosis, occlusion and changes in the blood flow². The halo sign seems to disappear between 2 days to 6 months after the beginning corticosteroid therapy^{3,4}.

The aim of this work is to highlight the importance of CDUS in the diagnostic workup of GCA and demonstrate its usefulness in the evaluation and documentation of the response to corticosteroid therapy.

A 70-year-old woman was prescribed 15 mg *id* of prednisolone for 9 months under a weaning scheme, for a polymyalgia rheumatica (PMR) diagnosed one year before. After suspending treatment, she complained of pain and stiffness of the shoulder girdle, and was, therefore, referred to a rheumatology consultation. The physical examination revealed an asymmetry in the arterial blood pressure of the upper limbs with non palpable brachial and radial peripheral pulses, bilaterally. Elevation of ESR 95 mm/1st hour and CRP 3,8 mg/dl, without changes in the remaining analytical study was noted. Mantoux test and thoracic-abdominal-pelvic computed tomography were also normal. Given the absence of the typical symptoms related to the involvement of the temporal artery, the biopsy was

not done. Instead of that, a CDUS of the cervical vessels and the temporal, axillary and brachial arteries was performed, that showed an extensive inflammatory process that suggested large vessel vasculitis with the typical halo in both carotid axes, as well as in the subclavian and axillary arteries producing significant stenosis and accelerations in vascular flow. The patient began a 1 mg/Kg *id* dosage of prednisolone, along with 100 mg *id* of acetylsalicylic acid, which resolved the PMR symptoms. 8 weeks later, she had a control CDUS that showed a significant improvement of the inflammatory changes associated to a reduction in the vascular flow velocity in the affected vessels (Figures 1 and

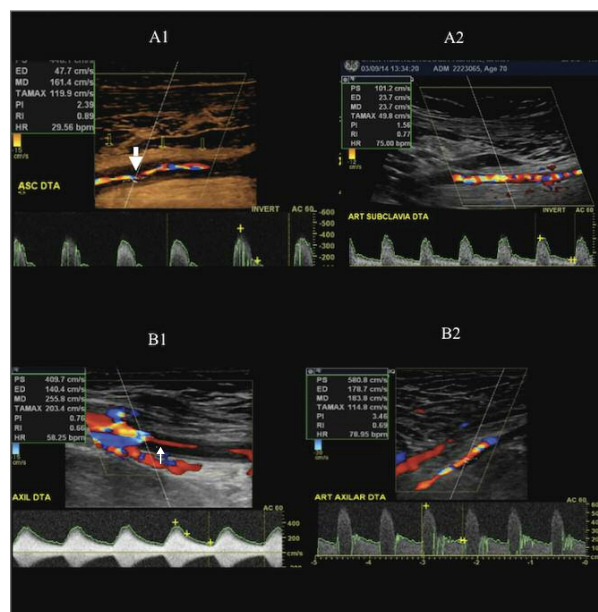


FIGURE 1. Longitudinal ultrasound images of right subclavian (A) and axillary (B) arteries. Halo sign (white arrow): hypoechoic area around the artery before the introduction of corticosteroids (A1 and B1); significant reduction of the halo thickness observed after eight weeks of treatment (A2 and B2).

1. Reumatologia, Hospital de Santa Maria, Centro Hospitalar Lisboa Norte, EPE; Hospital de São Teotónio, Centro Hospitalar Tondela-Viseu, EPE

2. Reumatologia, Hospital de Santa Maria, Centro Hospitalar Lisboa Norte, EPE

3. Reumatologia, Hospital de Santo Espírito de Angra do Heroísmo E.P.E.R

4. Laboratório de Hemodinâmica Cerebral do Serviço de Neurologia, Hospital de Santa Maria, Centro Hospitalar Lisboa Norte, EPE

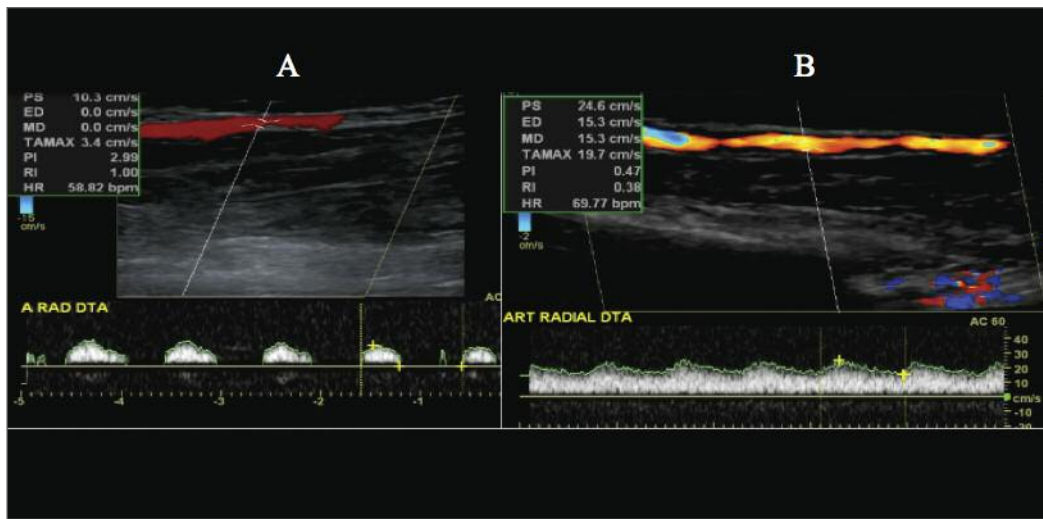


FIGURE 2. Ultrasound images of right radial artery: (A) short systolic spikes due to a serious deficit of distal perfusion of the vessel (B) After 8 weeks of treatment there is a significant improvement in the perfusion pressure, despite the persistence of a slow velocimetric curve. Also noteworthy is the reappearance of the diastolic component of the curve (absent in the image A).

2). Simultaneously, there was a significant fall of the inflammation parameters (ESR 6mm/1st hour, CRP 0,04 mg/dl). For 13 months the patient has remained asymptomatic and, at the moment, is receiving 15mg of prednisolone *id*. Temporal artery biopsy continues to be the *gold standard* in GCA diagnosis¹. However, recent studies show that the CDUS presents good sensitivity and specificity in diagnosing this pathology, with the advantage of being a non-invasive method. Besides this, a negative biopsy does not exclude GCA^{1,4,5}. In this case, the typical signs and symptoms of ACG were absent due to the predominant involvement of extra cranial branches. According to the literature, we agreed that due to the higher sensitivity associated with reasonable specificity CDUS should be performed in patients with suspected GCA as it will allow a conservative approach in a significant proportion of patients. Even in those requiring the biopsy, the CDUS maintains an important role in guiding the biopsy. Also noteworthy in the clinical case, besides the CDUS diagnostic potential, is its importance as a means of monitoring the response to treatment in patients with GCA, as well as in the detection of possible relapses.

CORRESPONDENCE TO

Nádia Martins
 Serviço de Reumatologia, Hospital de Santa Maria
 Av. Prof. Egas Moniz, 1649-035 Lisboa
 E-mail: nadia_filipaem@hotmail.com

REFERENCES

1. Ness T, Bley TA, Schmidt WA, Lamprecht P. The diagnosis and treatment of giant cell arteritis. *Dtsch Arztebl Int.* 2013; 110 (21):376-385
2. Schmidt WA, Kraft HE, Vorpahl K, Volker L, Gromnica-Ihle EJ. Color doppler ultrasonography in the diagnosis of temporal arteritis. *N Engl J Med* 1997; 337: 1336-1342.
3. Santoro L, D'Onofrio F, Bernardi S, Gremese E, Ferraccioli G, Santoliquido A. Temporal ultrasonography findings in temporal arteritis: early disappearance of halo sign after only 2 days of steroid treatment. *Rheumatology (Oxford)* 2013; 52(4):622.
4. De Miguel E, Roxo A, Castillo C, Peiteado D, Villalba A, Martín-Mola E. The utility and sensitivity of colour Doppler ultrasound in monitoring changes in giant cell arteritis. *Clin Exp Rheumatol.* 2012; 30 (70): 34-38.
5. Wolfgang A. Schmidt. Role of ultrasound in the understanding and management of vasculitis. *Ther Adv Musculoskelet Dis.* 2014; 6 (2): 39-47.