

Rare myositis-specific autoantibody associations among Hungarian patients with idiopathic inflammatory myopathy

Bodoki L¹, Nagy-Vincze M¹, Griger Z¹, Betteridge Z², Szöllösi L¹, Jobanputra R³, Dankó K¹

ACTA REUMATOL PORT. 2015;40:337-347

ABSTRACT

Idiopathic inflammatory myopathies are systemic, chronic autoimmune diseases characterized by symmetrical, proximal muscle weakness. Homogeneous groups present with similar symptoms. The response to therapy and prognosis could be facilitated by myositis-specific autoantibodies, and in this way, give rise to immunoserological classification. The myositis-specific autoantibodies are directed against specific proteins found in the cytoplasm or in the nucleus of the cells. To date, literature suggests the rarity of the co-existence of two myositis-specific autoantibodies. In this study the authors highlight rare associations of myositis-specific autoantibodies. Three hundred and thirty-seven Hungarian patients with polymyositis or dermatomyositis were studied. Their clinical findings were noted retrospectively. Specific blood tests identified six patients with the rare co-existence of myositis-specific autoantibodies, anti-Jo-1 and anti-SRP, anti-Jo-1 and anti-Mi-2, anti-Mi-2 and anti-PL-12, anti-Mi-2 and anti-SRP, and anti-SRP and anti-PL-7, respectively. This case review aims to identify the clinical importance of these rare associations and their place within the immunoserological classification.

Keywords: Anti-Mi-2; Anti-SRP; Idiopathic inflammatory myopathy; Anti-synthetase syndrome.

INTRODUCTION

Idiopathic inflammatory myopathies (IIM) are systemic autoimmune diseases characterized by symmetrical, proximal muscle weakness. Inflammation of skeletal muscles and internal organs underpin IIM, leading to irreversible damage and even death. The Bohan and Peter criteria is widely used for the diagnosis of IIM¹. Myositis is a disease with varied manifestations, and therefore an heterogeneous condition. With the help of myositis-specific autoantibodies (MSAs) we can divide patients, in most cases, into homogenous groups where the symptoms, response to therapy and prognosis are similar to each other. The MSAs are directed against specific proteins found in the cytoplasm or in the nucleus of the cells. It is proven²⁻⁴ that these autoantibodies have strong associations with clinical features and survival in adult and juvenile myositis patients (Table I). Autoantibodies preferentially associated with lung involvement are anti-Jo-1, anti-PL-7, anti-PL-12, anti-EJ, anti-OJ, anti-KS, anti-HA and anti-Zo (anti-amino-acyl-tRNA synthetase (ARS) autoantibodies)^{5,6}. Dermatomyositis (DM)-associated autoantibodies are anti-Mi-2 and the recently detected anti-MDA5, anti-TIF1 γ , anti-NXP2 and anti-SAE^{7,8}. Autoantibodies found in patients with necrotizing autoimmune myopathy (NAM) are anti-SRP and the recently recognized anti-200/100⁹⁻¹⁶. The autoantigen for anti-200/100 was recently identified as being 3-hydroxy-3-methylglutaryl-coenzyme A reductase (HMGCR)¹². Anti-Mup44 autoantibodies, which are targeted to cytosolic 5' nucleotidase 1A (cN1A), represent the first serological biomarker for sIBM (sporadic inclusion body myositis) and may facilitate the diagnosis of this type of myositis¹⁶. These autoantibodies distinguish IIM from acquired or genetic muscular disease. Cases have demonstrated a correlation between autoantibody titer and disease activity, thus predicting prognosis¹⁷.

1. Department of Clinical Immunology, Medical Faculty, University of Debrecen M^óricz Zs.

2. Bath Institute for Rheumatic Diseases, University of Bath, Bath, UK

3. Salford Royal Hospital, UK

TABLE 1. PATIENTS WITH DOUBLE MSA POSITIVITY IN OUR HUNGARIAN MYOSITIS POPULATION STUDIED

Age at diagnosis; gender	Diagnosis	CK level at disease onset (U/L)	Autoantibody positivity and ANA profile	Histopathological results	Muscle symptoms	Skin symptoms	Extramuscular manifestations	Therapy	Disease course
1. Patient 70; female	PM	5970	Jo-1 + SRP + ANA -	High variation of fibre calibre; endomyrial inflammation with macrophages and lymphocytes; MHC-I upregulation; no necrosis	Proximal muscle weakness	-	Dysphagia; pulmonary fibrosis; Raynaud's phenomenon	Steroid; cyclophosphamide	Chronic
2. Patient 49; female	DM	9210	Jo-1 + SRP + ANA -	Inflammatory infiltrates had perivascular and perimyrial location, also macrophages and neutrophils could be detected	Muscle weakness	Shawl-sign; V-sign; erythema on face	Raynaud's phenomenon; pulmonary fibrosis; arthralgia	Steroid; cyclophosphamide	Monophasic
3. Patient 50; female	PM	7890	Jo-1 + Mi-2 + ANA -	Endomyrial mononuclear cells (around and between myofibres); myonecrosis.	Proximal muscle weakness; myalgia	-	Pulmonary fibrosis	Steroid; azathioprine	Polyphasic
4. Patient 68; male	DM	62550	Mi-2 + PL-12 + ANA +	Very high variation of muscle fibre calibre; some necrotic fibres; no typical mononuclear cell infiltration; vacuolated muscle fibres	Extreme severe muscle weakness; myalgia	Heliotrop rash; erythema on face; shawl-sign; V-sign	Pulmonary fibrosis; dysphagia; arthralgia; Raynaud's phenomenon	Steroid	Monophasic
5. Patient 37; female	PM	7320	Mi-2 + SRP + ANA -	Focal invasion of muscle fibers by inflammatory cells; no vacuoles	Severe myalgia; proximal muscle weakness	-	-	Steroid; cyclosporine A; cyclophosphamide; intravenous immunoglobulin; methotrexate	Chronic
6. Patient 43; male	PM	70 (normal)	SRP + PL-7 + ANA -	Endomyrial mononuclear cell infiltration; normal muscle fibre calibre; no vacuoles	Myalgia; proximal muscle weakness	-	Arthralgia; dysphonia	Steroid; methotrexate	Polyphasic

(Abbreviations: ANA: antinuclear antibody; DM: dermatomyositis; MHC: major histocompatibility complex; PM: polymyositis; SRP: signal recognition particle)

This study aims to highlight rare associations of myositis-specific autoantibodies. Six Hungarian patients positive for double MSA have been studied. Clinically, these patients presented with muscle symptoms, skin lesions and extramuscular manifestations.

METHODS

PATIENTS

The Department of Clinical Immunology in the Medical Faculty at the University of Debrecen oversees five hundred and forty patients with IIM. The Myositis Antibody Research Project is coordinated together with the Bath Institute for Rheumatic Diseases. We evaluated the autoantibodies of 337 Hungarian patients diagnosed with myositis admitted to the University of Debrecen between 1990 and 2014¹⁸. The diagnosis of PM/DM was based on the Bohan and Peter criteria. We retrospectively collected their clinical data using the EuMyoNet database and patients' descriptions. All patients were either current or former patients at the University of Debrecen. This study is ethically compliant and was carried out in compliance with the Declaration of Helsinki¹⁹. Informed consent was obtained from all subjects.

ANTIBODY-DETECTION

The Regional Immunological Laboratory in Debrecen detected the following MSAs: anti-Jo-1, anti-PL-7, anti-PL-12, anti-Mi-2 and anti-SRP. These antibodies were detected by membrane-fixed immuno-blot (Orgentec Diagnostika). The method is briefly described. First, the contents of each vial of buffered wash solution concentrate were diluted with distilled water to a final volume of 1000 mL prior to use. A myositis plus strip was inserted and 1 mL of sample buffer was added to each chamber of the incubation tray. Then, it was equilibrated for 5 min with gentle rocking. 10 µL of sera was added to each chamber and incubated for 60 min at room temperature. Then, the diluted serum was removed from the strips. 2 mL of wash buffer was added; it was incubated for 5 min and then removed. This procedure had to be repeated twice. 1.0 mL of the enzyme conjugate was added to each chamber and incubated for 30 min. After removing the diluted conjugate, 2.0 mL of wash buffer was added and it was incubated for 5 min; then, it was removed and this step was repeated a further two times. After adding 1 mL of substrate to each strip, a 10 min incubation was per-

formed and, after removing the substrate, it was washed with 1 mL of distilled water, three times²⁰.

The recently discovered MSAs (anti-TIF1γ, anti-NXP2, anti-SAE and anti-MDA5) were detected in the UK by radiolabelled protein immunoprecipitation (IPP). Briefly, ten µL sera was mixed with 2 mg protein-A-Sepharose beads (Sigma, UK) in IPP buffer (10 mM Tris-Cl pH 8.0, 500 mM NaCl, 0.1% v/v Igepal) at room temperature for 30 min. Beads were washed in IPP buffer prior to the addition of 120 µL [35S] methionine labelled K562 cell extract. Samples were mixed at 4°C for 2 hr. Beads were washed in IPP buffer followed by TBS buffer (10 mM Tris-Cl pH 7.4, 150 mM NaCl) before being resuspended in 50 µL SDS sample buffer (Sigma, UK). After heating, proteins were fractionated by 10% SDS PAGE, enhanced, fixed and dried. Labelled proteins were analysed by autoradiography.

The antibody results for anti-Jo-1, anti-PL-7, anti-PL-12, anti-Mi-2 and anti-SRP were re-tested in Bath by IPP and the results were similar. Similarity means that nine anti-Jo-1 positive patients were only positive in Debrecen, eight anti-Jo-1 patients only in Bath. The cause of this difference was that some of the sera were not collected at the same time. This result confirms that the anti-Jo-1 positivity can disappear during disease progress²¹. Our reported six patients' results were the same in Bath and in Hungary. Anti-TIF1γ, anti-NXP2, anti-SAE and anti-MDA5 were only tested in Bath. Other anti-ARS autoantibodies (anti-EJ, anti-KS, anti-OJ, anti-Zo) were also tested in Bath; none of the patients were positive for these MSAs. Other MSAs (anti-200/100 and anti-Mup44) were tested neither in Hungary nor in the UK; this is one important limitation of our study.

MANUAL MUSCLE TESTING

The muscle strength of patients was defined by the manual muscle testing (MMT) score. MMT of proximal muscle groups has been used as a major end point for IIM therapeutic trials. It has also been used in clinical practice to follow patients longitudinally. Traditionally, MMT has been assessed using 5-point MMT scales, including the Medical Research Council Scale²². An expanded 0–10-point MMT scale²³ has also been used in recent therapeutic trials, which is postulated to be more sensitive in delineating weakness. Routinely, we also examined the following eight muscle groups on a 0–10 scale: neck flexors, musculus deltoideus, musculus biceps brachii, musculus gluteus maximus, mus-

culus gluteus medius, musculus quadriceps femoris, wrist extensors and ankle dorsiflexors. All muscle groups were assessed bilaterally, with the exception of the muscles of the neck. This together generated a maximum MMT score of 150 or a maximum MMT score of 80 (unilaterally).

ASSESSING THE PHYSICAL FUNCTION

The health assessment questionnaire (HAQ) was used to assess physical function. The HAQ disability index is designed to assess patients' usual abilities, disabilities and discomfort; it is based on the past week^{24,25}. Each questionnaire is graded with a score between 0 and 3, with three being the most unfavorable.

RESULTS

IMMUNOSEROLOGICAL CLASSIFICATION

All three hundred and thirty-seven patients were Caucasian. The mean age of the patients was 54.8 years (the oldest patient was 90 and the youngest patient was 9 years old); the women/men ratio was 2.9:1.

Among the three hundred and thirty-seven examined patients, there were one hundred and thirty-three positive MSA patients (39.5% of all patients with IIM) (Figure 1). Among the positive MSA patients sixty-two (46.6% of all MSA) were positive for anti-Jo-1 antibodies. In addition to the anti-Jo-1 antibody, two other anti-ARS antibodies could be detected. One of which was the anti-PL-7 autoantibody, with a total of four cases (3% of all MSA); and the anti-PL-12 autoantibody, with one case (0.8% of all MSA). We had 67 patients with anti-ARS positivity: 19.9% of all IIM patients and 50.4% of all MSA patients. Twenty-six patients, 19.6% of all MSA positive patients yielded anti-Mi-2 cases whilst fourteen cases, 10.5% of all MSA positive patients presented with anti-SRP positivity. We could detect anti-TIF1- γ positivity in twelve patients (9% of all MSA). Anti-SAE positivity was detected in four patients; anti-NXP-2 positivity was detected also in four patients (3%-3% of all MSA). Anti-MDA5 was not detected in any patients. Double MSA positivity was detected in six cases. This means that six patients had two MSAs in their sera. Two patients were positive for anti-Jo-1 and anti-SRP antibody (1.5% of all MSA). The other four patients (3% of all MSA) presented with anti-Jo-1 and anti-Mi-2; anti-Mi-2 and anti-SRP; anti-Mi-2 and anti-PL-12; and anti-SRP and anti-PL-7 antibodies.

PATIENTS WITH TWO MSAS

ANTI-JO-1 AND ANTI-SRP POSITIVITY

Two female patients tested positive for anti-Jo-1 and anti-SRP antibodies. The first patient, a seventy years old female, presented with acute onset of proximal muscle weakness without myalgia. Disability, fatigue and lethargy subsequently followed. In three months the patient lost sixteen kg weight. Laboratory testing showed elevated creatine phosphokinase (CK) (5970 U/L; normal range 24-195 U/L; Figure 2) and lactate dehydrogenase (LDH) (2860 U/L; normal range 135-220 U/L) and she had anti-Jo-1 positivity. Electromyography (EMG) showed typical myogen damage with myogen potentials. The muscle biopsy (m. deltoideus) showed a high variation of muscle fibre calibre, endomysial inflammation with macrophages and lymphocytes, and MHC-I upregulation. Necrosis was not detected. The patient had severe dysphagia in addition to Raynaud's phenomenon, mechanics hand, keratoconjunctivitis sicca and osteoporosis. Medically, methylprednisolone proved to be effective in the management of her symptoms. Regular physiotherapy improved the patients muscle strength. The patient was followed with high-resolution computed tomography (HRCT). One year after disease onset the patient developed alveolitis and then pulmonary fibrosis. Cyclophosphamide therapy was prescribed to reduce further deterioration of the lung function. Cyclophos-

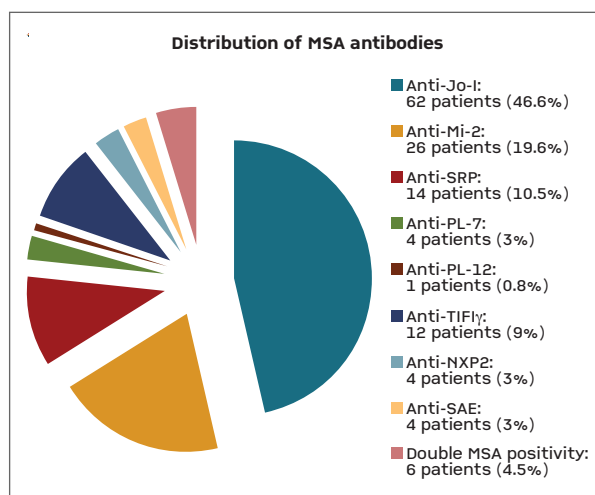


FIGURE 1. Immunoserological classification of our Hungarian patients with MSA positivity (Abbreviations: MSA: myositis-specific autoantibody; NXP2: nuclear matrix protein 2; SAE: small ubiquitin-like modifier activating enzyme; TIF1 γ : transcriptional intermediary factor 1 gamma)

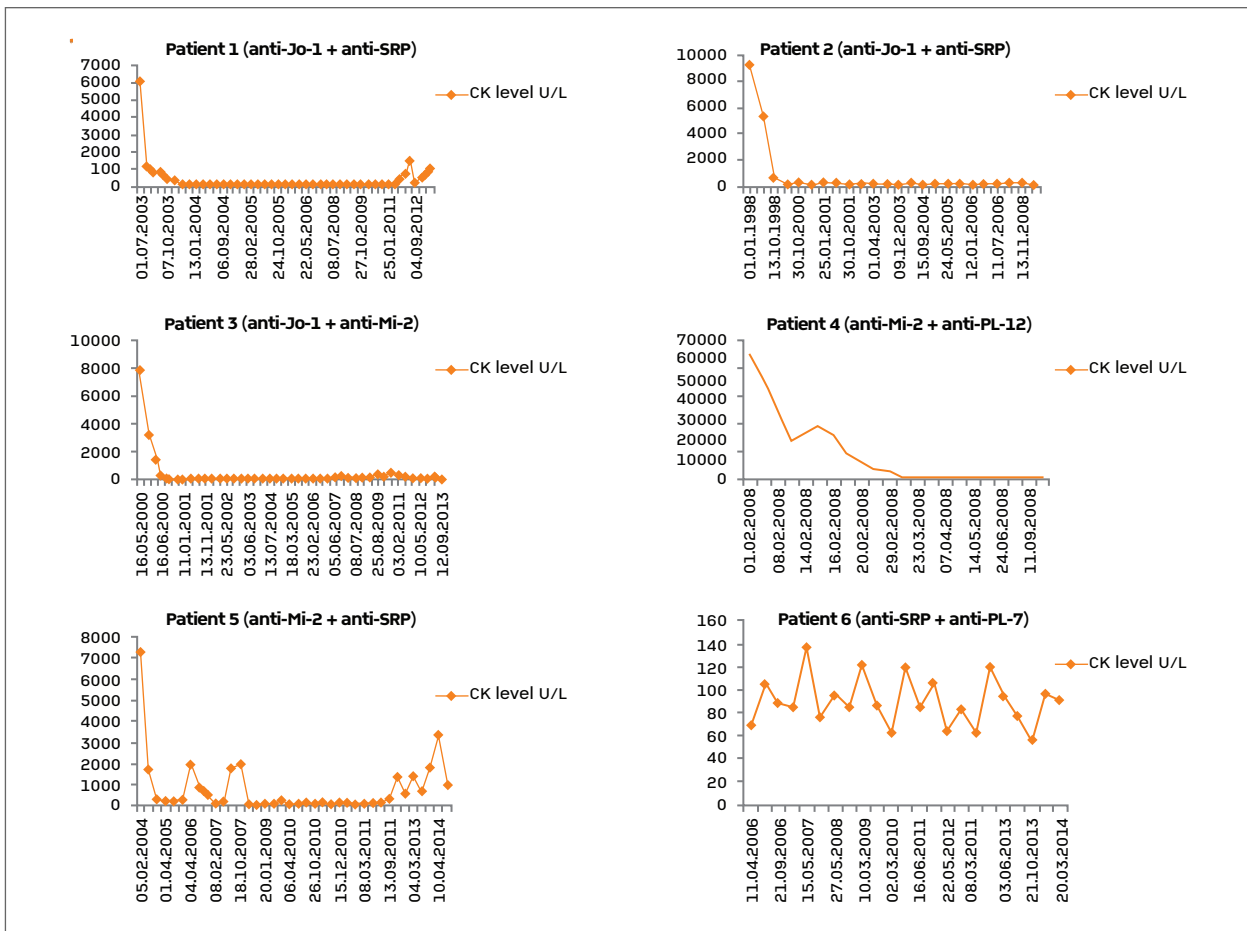


FIGURE 2. CK level of the six examined Hungarian patients with double MSA positivity (Abbreviations: CK: creatine phosphokinase; MSA: myositis-specific autoantibodies; SRP: signal recognition particle)

phamide therapy was repeated six times, and the patient was in a remissive state for several years. Five years after the onset she was diagnosed with anti-SRP positivity. During her last examination she had severe muscle weakness and myalgia (the MMT scores were 29/80 and 56/150), arthralgia, severe dysphagia and dyspnoea at exertion. Some months later – at the age of eighty - she died due to heart failure.

Our second patient was diagnosed with DM at the age of forty-nine: she had muscle weakness, arthralgia, Raynaud's phenomenon, shawl-sign and erythema on face. Laboratory tests gave an extremely high CK (9210 U/L; Figure 2), in addition to the anti-Jo-1 and anti-SRP positivity. The muscle biopsy was positive for DM. The inflammatory infiltration had perivascular and perimysial location, also macrophages and neutrophils could be detected in the involved area. EMG changes included myopathic motor unit potentials without

fibrillations. The result of HRCT at disease onset was pulmonary fibrosis. Treatment with methylprednisolone and cyclophosphamide was commenced. In the course of the year, skin involvement disappeared but muscular involvement progressed and worsened. Steroid therapy continued and a higher dose vastly improved proximal muscle strength. At present, the patient is sixty and is in remission with arthralgia being an intermittent presenting complaint.

ANTI-JO-1 AND ANTI-MI-2 POSITIVITY

The third patient with hypertension, obesity and carpal tunnel syndrome presented with her first muscular symptoms aged fifty. In this case, proximal muscle weakness and myalgia were present. The laboratory values showed elevated CK (at first measurement 7890 U/L; Figure 2), and LDH levels (at first measurement 1396 U/L). EMG showed fibrillation at rest, polypha-

tic potentials of short duration and low amplitude, spontaneous and positive sharp waves. The muscle biopsy showed endomysial mononuclear cells (around and between myofibres) and also myonecrosis. HRCT showed alveolitis and lung fibrosis; the patient complained about dyspnoea. The autoantibody detection confirmed anti-Jo-1 and anti-Mi-2 positivity. Methylprednisolone was prescribed initially which subsequently improved muscle strength. This however was short lived, myalgia and loss of proximal muscle function progressed within six months. Upper limb was also involved as IIM advanced. Azathioprine was greatly beneficial and dissolved her symptoms. Now the patient is sixty-four years of age, in remission and free of symptoms and immunosuppressive therapy. She has neither skeletal, nor gastrointestinal, nor cardiovascular disease activity. She is regularly controlled with HRCT; the lung fibrosis is only present at the basis of the lung and she has no dyspnoea. The muscle disease is also inactive: the MMT scores during the last four examinations were 77/80 and 143/150; 78/80 and 147/150; 78/80 and 147/150; 71/80 and 134/150; respectively. Serum levels of muscle enzymes were within normal range.

ANTI-MI-2 AND ANTI-PL-12 POSITIVITY

The fourth patient had very severe myalgia and became very weak at the age of sixty-eight. His disease was very progressive DM. At disease onset he had stationary fever (38°C or higher), heliotrope rash, erythema on his face, shawl-sign, Raynaud's phenomenon, dysphagia and arthralgia. EMG showed myopathic pattern with spontaneous activity and polyphasic potentials of short duration. Interestingly, muscle biopsy showed a very high variation of muscle fibre calibre and some necrotic fibres. Some lymphocytes were present but the typical mononuclear cell infiltration could not be detected. Vacuolated muscle fibres were also present. He had severe lung involvement: alveolitis and fibrosis – according to the result of HRCT and DLCO test. CK level was extremely high, 62550 U/L and this extreme level lasted more than one month (Figure 2). Other laboratory parameters: LDH 5298 U/L, serum glutamic oxaloacetic transaminase (SGOT) 1841 U/L (normal range <40 U/L), serum glutamic pyruvic transaminase (SGPT) 381 U/L (normal range <40 U/L). His serum was anti-Mi-2 and anti-PL-12 positive. According to the biopsy findings IBM could also have been a possible diagnosis; but it was excluded as the duration of illness was not more than six months and distal mus-

cles were not affected. The patient was commenced on a high dose of steroid. The patient's symptoms progressed unfavorably and before his death due to aspiration pneumonia at sixty-eight, he was bedridden.

ANTI-MI-2 AND ANTI-SRP POSITIVITY

Our next patient presented with myalgia at aged thirty-seven. Myalgia was presented bilaterally in the musculus quadriceps femoris. The patient was unable to climb stairs and had proximal muscle weakness with upper limb involvement. The patient did not have any extramuscular involvement. CK level was 7320 U/L (Figure 2), the LDH level was 21087 U/L. The CK-MB level was also high (579 U/L), she had troponin-T positivity. Her serum was positive for anti-Mi-2 and anti-SRP antibodies. The characteristic triad of increased insertional activity, spontaneous, bizarre high-frequency discharges and polyphasic motor unit potentials of low amplitude and short duration could be detected with EMG. The muscle biopsy showed focal invasion of muscle fibers by inflammatory cells and no vacuoles. She got pulse methylprednisolone therapy. She was treated with cyclosporine A, cyclophosphamide, methotrexate and finally with intravenous immunoglobulin. This was effective but the patient still requires steroid and methotrexate therapy. She currently shows signs of chronic myositis with generalized fatigue and muscle weakness. Her MMT scores during the last two examinations were 57/80 and 105/150; 55/80 and 94/150 respectively.

ANTI-SRP AND ANTI-PL-7 POSITIVITY

The female patient had her first symptoms at the age of forty: myalgia, fatigue, proximal muscle weakness. CK level and LDH level were not high, no antibody was detectable, EMG was negative and muscle biopsy was unremarkable. She was treated with steroid, in the next three years she had only some weakness in her limbs. Then, at the age of forty-three, she could not climb the stairs because she had severe weakness and general fatigue. Both EMG and muscle biopsy were conducted and the diagnosis of PM was given. The muscle biopsy showed endomysial mononuclear cell infiltration, muscle fibre calibre was normal and no vacuoles were visible. EMG showed fibrillation at rest and polyphasic potentials of short duration and low amplitude. Her serum was positive for anti-SRP and anti-PL-7 antibodies. Interestingly, CK level remained at normal levels (Figure 2). She got higher dose of methylprednisolone and methotrexate. Now – with this therapy – she is in

TABLE II. MYOSITIS-SPECIFIC AUTOANTIBODIES AND CLINICAL ASSOCIATIONS^{2,5,10,16}

Myositis-specific autoantibodies	Target autoantigen	Clinical features	Frequency in adults (IIM%)	Frequency in juvenile patients (IIM%)
1. Anti-ARS	Amino-acyl-tRNA synthetase	ASS: - myositis - symmetrical non-erosiv arthritis - Raynaud's phenomenon - ILD - fever - mechanic's hand	30-40%	1-3%
Anti-Jo-1	Histidyl	Classical ASS	15-20%	
Anti-PL-7	Theronyl	ILD before myositis	<5%	
Anti-PL-12	Alanyl	ILD before myositis	<5%	
Anti-EJ	Glycyl	Chronic, therapy refracter ILD	<5%	
Anti-OJ	Isoleucyl	Chronic, therapy refracter ILD	<5%	
Anti-KS	Asparaginyll		<5%	
Anti-HA	Tyrosyl		<1%	
Anti-Zo	Phenylalanyl		<1%	
2. Anti-Mi-2	Nucleosome remodeling deacetylase complex (NuRD)	DM: - in general mild progress	<10%	4-10%
3. Anti-SRP	Signal recognition particle (SRP)	PM, NAM: - in general rapid progress - severe myositis - severe cardiac involvement - severe dysphagia	5%	<3%
4. Anti-SAE	Small ubiquitin-like modifier activating enzyme (SAE)	DM: - severe skin lesions - adults: dysphagia	<5%	<1%
5. Anti-TIF1γ	Transcriptional intermediary factor 1 gamma (TIF1-γ)	DM: - adults: DM + malignancy - juvenile: DM + ulcers	13-21%	23-29%
6. Anti-MDA-5	Melanoma differentiation-associated gene 5 (MDA5)	DM: - ulcers - mild myositis - arthritis - ILD	not exactly known	not exactly known
7. Anti-NXP2	Nuclear matrix protein 2 (NXP2)	DM: - adults: severe DM + malignancy - juvenile: DM + calcinosis	<5%	23-25%
8. Anti-200/100	3-hydroxy-3-methylglutaryl-coenzyme A reductase (HMGCR)	Statin induced NAM: - in general rapid progress - severe myositis - severe cardiac involvement - severe dysphagia	<10%	not exactly known
9. Anti-Mup44	Cytosolic 5'-nucleotidase 1A (cN1A)	IBM	4% (in IBM: 33%)	

(Abbreviations: ARS: amino-acyl-tRNA synthetase; ASS: anti-synthetase syndrome; cN1A: cytosolic 5'-nucleotidase 1A; DM: dermatomyositis; HMGCR: 3-hydroxy-3-methyl-glutaryl-CoA reductase; IBM: inclusion body myositis; IIM: idiopathic inflammatory myopathy; ILD: interstitial lung disease; MDA5: melanoma differentiation-associated gene 5; NAM: necrotizing autoimmune myopathy; NXP2: nuclear matrix protein 2; PM: polymyositis; SAE: small ubiquitin-like modifier activating enzyme; SRP: signal recognition particle; TIF1γ: transcriptional intermediary factor 1 gamma)

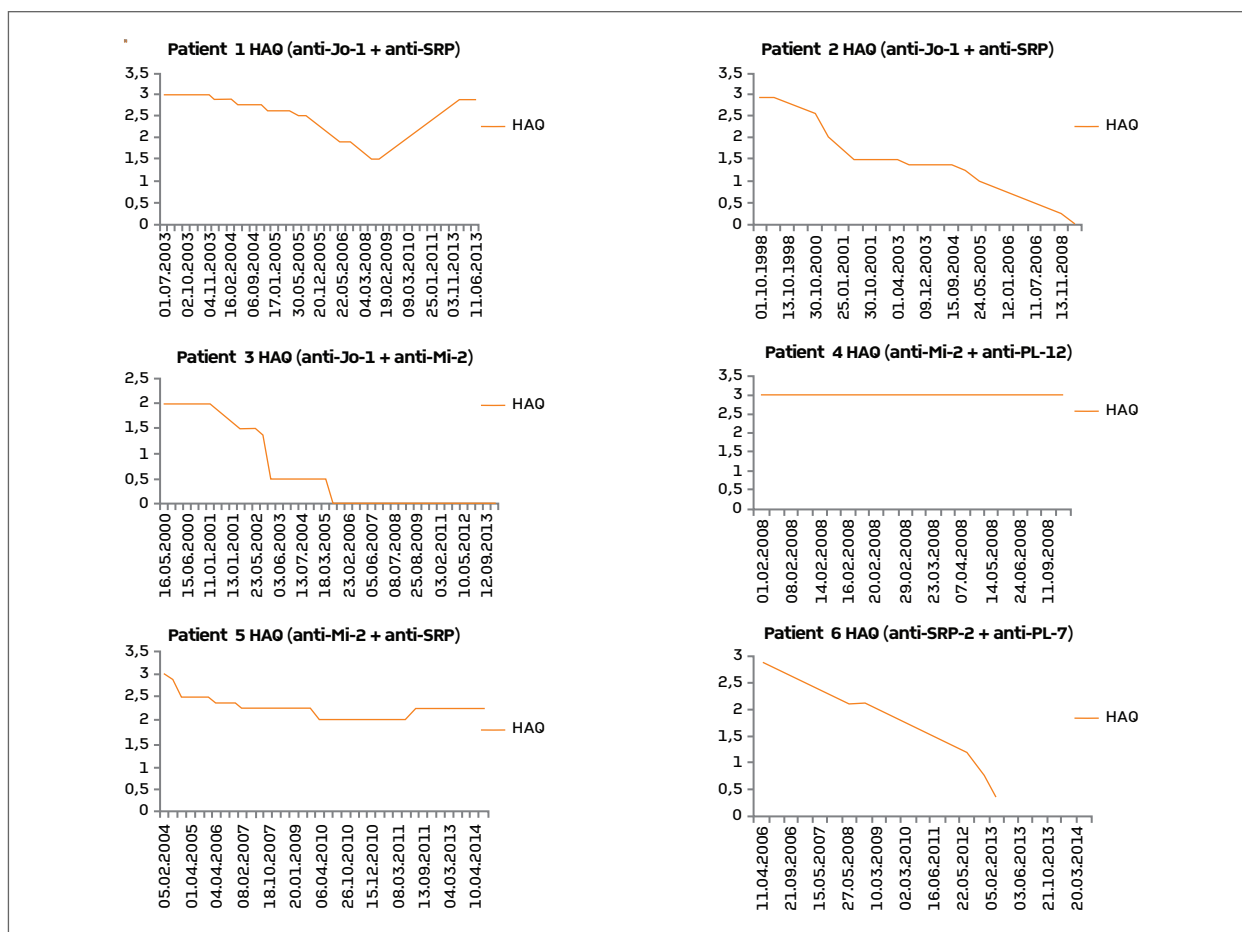


FIGURE 3. HAQ score of the six examined Hungarian patients with double MSA positivity (Abbreviations: HAQ: health assessment questionnaire; MSA: myositis-specific autoantibody; SRP: signal recognition particle)

remission, she does gymnastics regularly. She has mild arthralgia, mild dysphonia and mild myalgia. Her MMT scores during the last four investigations were 65/80 and 121/150; 62/80 and 116/150; 65/80 and 122/150; 63/80 and 117/150; respectively.

The most important results about these six patients are summarized in Table II. CK level and HAQ score can be followed in Figures 2 and 3.

DISCUSSION AND LITERATURE REVIEW

MSAs are clearly a useful diagnostic tool. It can be further argued that they are useful for identifying distinct subsets. Autoantibodies - as shown - can be therefore used as specific markers for myositis. 36% of patients have MSA in their sera²⁶, and the majority of patients have only one MSA. Our study represents however a

few exceptions and is of great interest to physicians. This cohort is of importance because there is very limited information about such cases in the literature. We draw clinicians' attention to our set of cases that were diagnosed with double MSA positivity.

Koenig *et al.* reported that a significant proportion of IIM patients are characterized by complex associations of autoantibodies. It is important that they did not report about the coexistence of two or more MSAs, only about the associations of MSAs and MAAs²⁷.

Our literature review is summarised in Table III. At first Gelpí *et al.*²⁸ described the immunologic findings of a patient whose serum showed two different antibodies: anti-Jo-1 and anti-OJ. These are two of the eight anti-ARS antibodies²⁹; the anti-synthetase syndrome (ASS) is characterized by myositis, interstitial lung disease (ILD), symmetrical non-erosive arthritis, Raynaud's phenomenon, fever and mechanic's hands³⁰. The

TABLE III. RESULTS OF PREVIOUS STUDIES AND CASE REPORTS ABOUT IIM PATIENTS WITH DOUBLE MSA POSITIVITY

Study	Patient diagnosis (gender)	MSA positivity	ANA profile	Clinical features	Treatment	Prognosis
Gelpí et al. (1996) ²⁸	PM (F)	anti-Jo-1 anti-OJ	+	ASS with arthritis, ILD, myositis	steroid azathioprine	good clinical response
Sugie et al. (2012) ³³	DM, CAM (M)	anti-Jo-1 anti-SRP	+	progressive, muscle weakness, pleural effusion, ILD	steroid	4 month after onset: papillary adenocarcinoma of stomach; gastrectomy; died of ILD and liver metastases
Nakajima et al. (2012) ³⁹	PM-RA overlap (M)	anti-Jo-1 anti-PL-7	+	polyarthritis, myositis, ILD	no data	good
	PM-RA overlap (M)	anti-Jo-1 anti-PL-7	-	polyarthritis, myositis, ILD	no data	good
	PM-RA overlap (F)	anti-PL-7 anti-SRP	+	PM-RA overlap	no data	good
Malkan et al. (2015) ³⁴	NAM (F)	anti-PL-12 anti-SRP	no data	NAM ASS	steroid IVIG azathioprine cyclophosphamide rituximab	good improvement

ANA: antinuclear antibody; ASS: anti-synthetase syndrome; CAM: cancer-associated myositis; DM: dermatomyositis; F: female; IIM: idiopathic inflammatory myopathy; ILD: interstitial lung disease; IVIG: intravenous immunoglobulin; M: male; MSA: myositis-specific antibody; NAM: necrotizing autoimmune myopathy; PM: polymyositis; RA: rheumatoid arthritis; SRP: signal recognition particle

patient with anti-Jo-1 and anti-OJ had prominent arthritis, lung fibrosis and subclinical myositis as part of the ASS. Five of our patients showed ARS positivity. All anti-Jo-1 positive patients and the patient with anti-PL-12 had typical pulmonary fibrosis during disease course. The exception was the patient with anti-PL-7 positivity who had no lung involvement.

Anti-SRP positivity correlates with severe and progressive necrotizing myositis (NAM), and poor prognosis^{31,32}. The case of Sugie *et al.*³³ is of great importance in connection with our study; their patient is the only one in the literature who had the same antibodies as two of our patients: anti-Jo-1 and anti-SRP. The sixty-one year old man had DM, progressively worsening of muscle weakness, pleural effusion and ILD. He died of papillary adenocarcinoma of the stomach because it was a cancer-associated myositis. Our first patient also

acquired pulmonary fibrosis and Raynaud's phenomenon, as part of the anti-Jo-1 positive PM. Anti-SRP positivity was also associated with the typical, progressively worsening myositis. Our second patient had DM, muscle weakness and ILD; in contrast with the cited case she had a monophasic disease and is in remission. Malkan *et al.*³⁴ also reported a combination of NAM and ASS with the rare finding of two MSAs: anti-SRP and anti-PL-12. The patient needed more aggressive immunotherapy but showed good improvement. Our patient with anti-SRP and anti-PL-7 – as mentioned above – is in contrast with these cases. She had myalgia, proximal muscle weakness and arthralgia; these are specific symptoms neither for anti-SRP nor for anti-PL-7. Her normal CK levels are notable, because lower (but not normal) CK levels in patients with anti-PL-7 positivity were observed by Marie *et al.*³⁵.

Our cohort is the first that describes anti-Mi-2 positive patients having another MSA. Traditionally anti-Mi-2 is strongly associated with severe skin lesions but good response to therapy³⁶⁻³⁸. Other studies said that anti-Mi-2 can also be detected in PM²⁶. Three of our six patients with MSA coexistence had anti-Mi-2 positivity. The PM/DM ratio was 2:1. One female patient had anti-Jo-1 positivity and PM. She had muscle symptoms and pulmonary fibrosis but no skin involvement. The male patient had anti-PL-12 positivity and DM. According to Marie *et al.*³⁵ the presence of anti-PL12 autoantibody is markedly associated with early and severe ILD and gastrointestinal complications. Our male patient showed DM with heliotrope rash, erythema on face, shawl-sign, V-sign – these are typical for anti-Mi-2 positive DM. He also had extremely high level of CK, severe acute ILD, high fever, Raynaud's phenomenon and arthralgia – these are the classical signs of the ASS. The second female patient was diagnosed with anti-SRP positivity and PM. She has a chronic form of PM without skin symptoms and cardiovascular disease activity. In this case we could not diagnose the signs of anti-SRP or anti-Mi-2 positivity.

Nakajima *et al.*³⁹ investigated twelve patients with IIM-RA overlap. Two out of twelve patients were concurrently positive for two different MSAs: anti-Jo-1 and anti-PL-7 antibodies. Both of the patients in this study were males with mild polyarthritis, mild myositis and mild ILD. One out of twelve patients was positive for anti-PL-7 and anti-SRP but not at the same time.

CONCLUSION

MSAs, which characterize certain forms of inflammatory myopathy, are useful in the diagnosis and prediction of prognosis in DM/PM. Sugie *et al.*³³ alleged that the coexistence of two MSAs leads to more severe symptoms, interacting in a complex fashion, thus expanding the clinical spectrum of IIM. Investigating six patients with two MSAs in our Hungarian IIM population we conclude the followings. It cannot be stated that these associations all have a more serious course or a more severe phenotype. Only one patient died of an extreme severe form of myositis. We can state that only two patients matched the characteristic features of both antibodies; two patients fitted one antibody's anticipated symptoms; two patients had simple clinical manifestations represented only with weakness and myalgia. Based on these results and the literature re-

view the presence of more than one MSA is rather associated with a "mixture" of phenotypes. In clinical practice the presence of one or two MSAs should be carefully interpreted. The main message of this work is that the physician has to evaluate these findings together with the clinical features.

CORRESPONDENCE TO

Bodoki L
Department of Clinical Immunology, Medical Faculty,
University of Debrecen Móricz Zs. krt. 22. H-4032
Debrecen, Hungary
E-mail: bodoki.levente@gmail.com

REFERENCES

- Bohan A, Peter JB. Polymyositis and dermatomyositis. *N Engl J Med.* 1975;292:344-7.
- Tansley SL, Betteridge ZE, McHugh NJ. The diagnostic utility of autoantibodies in adult and juvenile myositis. *Curr Opin Rheumatol.* 2013;25:772-777.
- Targoff, I. N. Update on myositis-specific and myositis-associated autoantibodies. *Curr Opin Rheumatol.* 2000;12:475-481.
- Lowry CA, Pilkington CA. Juvenile dermatomyositis: extramuscular manifestations and their management. *Curr Opin Rheumatol.* 2009;21:575-580.
- Betteridge Z, Gunawardena H, McHugh NJ. Novel autoantibodies and clinical phenotypes in adult and juvenile myositis. *Arthritis Research and Therapy* 2011;13:209. doi: 10.1186/ar3275.
- Koreeda Y, Higashimoto I, Yamamoto M, et al. Clinical and pathological findings of interstitial lung disease patients with anti-aminoacyl-tRNA synthetase autoantibodies. *Intern Med.* 2010;49:361-369.
- Casciola-Rosen L, Mammen AL. Myositis autoantibodies. *Curr Opin Rheumatol.* 2012;24:602-608.
- Betteridge ZE, Gunawardena H, Chinoy H, et al. Clinical and human leucocyte antigen class II haplotype associations of autoantibodies to small ubiquitin-like modifier enzyme, a dermatomyositis-specific autoantigen target, in UK Caucasian adult-onset myositis. *Ann Rheum Dis.* 2009;68:1621-1625.
- Rojana-udomsart A, Mitrpant C, Bundell C, et al. Complement-mediated muscle cell lysis: a possible mechanism of myonecrosis in anti-SRP associated necrotizing myopathy (ASANM). *J Neuroimmunol.* 2013;264:65-70.
- Allenbach Y, Drouot L, Rigolet A, et al. Anti-HMGCR Autoantibodies in European Patients With Autoimmune Necrotizing Myopathies: Inconstant Exposure to Statin. *Medicine (Baltimore).* 2014;93:150-157.
- Christopher-Stine L, Casciola-Rosen LA, Hong G, Chung T, Corse AM, Mammen AL. A novel autoantibody recognizing 200-kd and 100-kd proteins is associated with an immune-mediated necrotizing myopathy. *Arthritis Rheum.* 2010;62:2757-2766.
- Mammen AL, Chung T, Christopher-Stine L, et al. Autoantibodies against 3-hydroxy-3-methylglutaryl-coenzyme A reductase in patients with statin-associated autoimmune myopathy. *Arthritis Rheum.* 2011;63:713-721.
- Basnayake SK, Blumbergs P, Tan JA, Roberts-Thompson PJ, Limaye V. Inflammatory myopathy with anti-SRP antibodies: case series of a South Australian cohort. *Clin Rheumatol.* 2014.
- Wang L, Liu L, Hao H, et al. Myopathy with anti-signal recognition particle antibodies: clinical and histopathological fea-

- res in Chinese patients. *Neuromuscul Disord.* 2014;24:335-341.
15. Drouot L, Allenbach Y, Jouen F, et al. Exploring necrotizing autoimmune myopathies with a novel immunoassay for anti-3-hydroxy-3-methyl-glutaryl-CoA reductase autoantibodies. *Arthritis Res Ther.* 2014;16:R39.
 16. Pluk H, van Hoeve BJ, van Dooren SH, et al. Autoantibodies to cytosolic 5'-nucleotidase 1A in inclusion body myositis. *Ann Neurol.* 2013;73:397-407.
 17. Sato, S., Kuwana, M., Fujita, T., Suzuki Y. Anti-CADM-140/MDA5 autoantibody titer correlates with disease activity and predicts disease outcome in patients with dermatomyositis and rapidly progressive interstitial lung disease. *Mod Rheumatol.* 2013;23:496-502.
 18. Bodoki L, Nagy-Vincze M, Griger Z, Betteridge Z, Szöllösi L, Dankó K. Four dermatomyositis-specific autoantibodies-anti-TIF1, anti-NXP2, anti-SAE and anti-MDA5-in adult and juvenile patients with idiopathic inflammatory myopathies in a Hungarian cohort. *Autoimmun Rev.* 2014;13:1211-1219.
 19. World Medical Association. World Medical Association Declaration of Helsinki: ethical principles for medical research involving human subjects. *JAMA.* 2013;310:2191-2194.
 20. ORGENTEC Diagnostika GmbH Myositis plus Instruction for use. http://www.orgentec.com/products/pdfs/IFU_ELISA_Blot_EN/ORG%20760_IFU_EN_QM113220_2012-11-27_1.1.pdf
 21. Maddison PJ. Aminoacyl-tRNA histidyl (Jo-1) synthetase autoantibodies. In: Peter JB, Shoenfeld Y, ed. *Autoantibodies.* Amsterdam: Elsevier 1996:31-34.
 22. Kendall FP, McCreary EK, Provance PG. *Muscles: testing and function.* 4th ed. Baltimore: Williams and Wilkins; 1993.
 23. Targoff IN, Mamyrova G, Trieu EP, et al. A novel autoantibody to a 155-kd protein is associated with dermatomyositis. *Arthritis Rheum.* 2006;54:3682-3689.
 24. Alexanderson H, Lundberg IE, Stenström CH. Development of the myositis activities profile—validity and reliability of a self-administered questionnaire to assess activity limitations in patients with polymyositis/dermatomyositis. *J Rheumatol.* 2002;29:2386-2392.
 25. The Health Assessment Questionnaire (Haq) Disability Index (Di) of the Clinical Health Assessment Questionnaire (Version 96.4): http://www.niehs.nih.gov/research/resources/assets/docs/haq_instructions.pdf
 26. Brouwer R, Hengstman GJ, Vree Egberts W, et al. Autoantibody profiles in the sera of European patients with myositis. *Ann Rheum Dis.* 2001;60:116-123.
 27. Koenig M, Fritzler MJ, Targoff IN, Troyanov Y, Senécal JL. Heterogeneity of autoantibodies in 100 patients with autoimmune myositis: insights into clinical features and outcomes. *Arthritis Res Ther.* 2007;9:R78.
 28. Gelpi C, Kanterewicz E, Gratacos J, Targoff IN, Rodríguez-Sánchez JL. Coexistence of two antisynthetases in a patient with the antisynthetase syndrome. *Arthritis Rheum.* 1996;39:692-697.
 29. Mahler M, Miller FW, Fritzler MJ. Idiopathic inflammatory myopathies and the anti-synthetase syndrome: a comprehensive review. *Autoimmun Rev.* 2014;13:367-371.
 30. Häussermann A, Gillissen A, Seidel W. [The anti-Jo-1 syndrome – a specific form of myositis with interstitial lung disease]. [Article in German] *Pneumologie.* 2010;64:496-503.
 31. Rouster-Stevens KA, Pachman LM. Autoantibody to signal recognition particle in African American girls with juvenile polymyositis. *J Rheumatol.* 2008;35:927-929.
 32. Suzuki S. [Anti-SRP myopathy: different entity from myositis]. [Article in Japanese]. *Rinsho Shinkeigaku.* 2012;52:1148-1150.
 33. Sugie K, Tonomura Y, Ueno S. Characterization of dermatomyositis with coexistence of anti-Jo-1 and anti-SRP antibodies. *Intern Med.* 2012;51:799-802.
 34. Malkan A, Cappelen-Smith C, Beran R, et al. Anti-synthetase syndrome associated with anti PL-12 and anti-Signal recognition particle antibodies and a necrotizing auto-immune myositis. *J Clin Neurosci.* 2015;22:396-398.
 35. Marie I, Josse S, Decaux O, et al. Comparison of long-term outcome between anti-Jo1- and anti-PL7/PL12 positive patients with antisynthetase syndrome. *Autoimmun Rev.* 2012;11:739-745.
 36. Hamaguchi Y, Kuwana M, Hoshino K, et al. Clinical correlations with dermatomyositis-specific autoantibodies in adult Japanese patients with dermatomyositis: a multicenter cross-sectional study. *Arch Dermatol.* 2011;147:391-398.
 37. Selva-O'Callaghan A, Labrador-Horrillo M, Solans-Laque R, Simeon-Aznar CP, Martínez-Gómez X, Vilardell-Tarrés M. Myositis-specific and myositis-associated antibodies in a series of eighty-eight Mediterranean patients with idiopathic inflammatory myopathy. *Arthritis Rheum.* 2006;55:791-798.
 38. Ghirardello A, Bassi N, Palma L, et al. Autoantibodies in polymyositis and dermatomyositis. *Curr Rheumatol Rep.* 2013;15:335.
 39. Nakajima A, Yoshino K, Soejima M, et al. High frequencies and co-existing of myositis-specific autoantibodies in patients with idiopathic inflammatory myopathies overlapped to rheumatoid arthritis. *Rheumatol Int.* 2012;32:2057-2061.