

Neuromuscular manifestations of primary biliary cholangitis: two case reports and literature review

Brites L¹, Ribeiro J², Luis M¹, Santiago M¹, Negrão L², Duarte C¹

ACTA REUMATOL PORT. 2018;43:304-308

ABSTRACT

Primary biliary cholangitis (PBC) is a rare chronic disease, characterized by progressive cholestasis that could end in end-stage liver disease. Its diagnosis is based in the presence of a cholestatic pattern and antimitochondrial antibodies. Neurological complications of PBC are unusual, but there are descriptions of association with myopathies and neuropathies, being polymyositis the most frequent. We report two cases of patients with the diagnosis of PBC with neurologic complications: one case with asymptomatic PBC and myopathy and another one with demyelinating neuropathy. Neurologic diseases in patients with PBC have been described mainly as case reports. The co-occurrence of both entities suggests the possible existence of a common pathogenic mechanism but the real etiopathogeny is still unknown.

Keywords: Primary biliary cholangitis; Autoimmunity; Myopathy.

INTRODUCTION

Primary biliary cholangitis (PBC) is a rare inflammatory autoimmune chronic disease, characterized by progressive cholestasis that can ending in end-stage liver disease¹. The etiology and mechanisms underlying PBC pathogenesis remain unknown, although some authors presumed some autoimmune involvement^{2,3}. It is more frequent in female gender, especially after fourth decade of life¹ with prevalence rates ranging from 1.91 to 40.2 per 100,000 inhabitants⁴.

PBC diagnosis is based in the presence of a cholestatic pattern and antimitochondrial antibodies (AMAs) in the serum tests of the patient¹. The serological hallmark of PBC is the presence of circulating AMAs. AMAs are found in 95% of cases of PBC with specificity close to 98%^{2,3,5}. Despite its specificity for this disease, their pathogenic role is uncertain⁵. Antinuclear antibodies (ANAs) can also be identified in about 30% of patients with PBC¹. Other abnormalities on laboratory studies include elevation of cholestasis (alkaline phosphatase (ALP), γ -glutamyl transpeptidase (GGT)) and cytolysis enzymes (alanine aminotransferase (ALT) and aspartate aminotransferase (AST)), elevation of IgM levels, increased lipid and cholesterol levels and increased erythrocyte sedimentation rate. According to the European Association for the Study of the Liver Clinical Practice Guidelines, liver biopsy is recommended in the cases of unexplained intrahepatic cholestasis serologic and imaging tests¹. Histologically, it is characterized by loss of biliary epithelial cells and destruction of small and medium intrahepatic bile ducts with portal infiltration of T and B cells, macrophages, eosinophils and natural killer cells^{5,6}.

Neuromuscular complications of PBC are unusual, but there are descriptions of association with myopathies and neuropathies. Polymyositis is one of the most mentioned in the available literature. The prevalence of PBC in inflammatory myopathies is unknown and clinical and histopathological features of this association have not yet been clarified⁵. Peripheral neuropathy is a less well recognized complication in non-alcoholic liver disease.

A Pubmed research since 1990 revealed some case reports on PBC in association with myopathies or neuropathies, which was generally found to be polymyositis and peripheral sensory neuropathy, respectively.

We report two cases of patients with the diagnosis of PBC with neuromuscular complications: one case with myopathy and another one with peripheral neuropathy.

1. Serviço de Reumatologia, Centro Hospitalar e Universitário de Coimbra, Coimbra

2. Unidade de Doenças Neuromusculares, Serviço de Neurologia, Centro Hospitalar e Universitário de Coimbra, Coimbra

CASE REPORTS

PATIENT 1

A 56-year-old woman presented with a two-week history of peripheral arthritis and myalgias in the left upper limb that have progressed to generalized myalgias two months after. She had been diagnosed with PBC 9 years before based on the presence of pruritus and fatigue; increased levels of ALP (190 U/L, reference value <120) and GGT (70 U/L, reference value <55), AMAs (titer 1280), anti-Pyruvate Dehydrogenase IgG-M2 (150U/mL; reference value <4) and hepatomegaly (described on an abdominal ultrasound). Besides her complaints about pruritus and fatigue, so far she was totally asymptomatic. She started medication with ursodesoxicolic acid and an emollient cream with a good response after 6 months (ALP 100U/L and GGT 40U/L).

At the time of the PBC diagnosis she denied any alcohol consumption and she didn't do any medication. Nine years after this diagnosis, she started complaints of peripheral arthritis on her hands and feet and myalgias in the left upper limb. Her blood tests revealed a newly increase of some muscle enzymes level: AST of 43U/L (reference value <31), ALT of 61 (reference value <34), ALP 120U/L, creatine kinase (CK) of 323U/L (reference value <145) and lactate dehydrogenase (LDH) of 275 U/L (reference value <247). At this time, she was referred to our rheumatology department to further investigations.

Two months after her initial symptoms, she referred the same joint complaints but with progression of the

left upper limb myalgias to generalized myalgias. When asked, she denied cutaneous, ocular, respiratory, gastrointestinal or genitourinary manifestations. She didn't have constitutional symptoms (anorexia, fever or weight loss), dysphagia, dyspnea, muscle weakness or gait changes. There was a worsening of muscle enzyme levels: AST 38U/L, ALT 64U/L, CK 524U/L, LDH 318 U/L and aldolase 19.4 U/L (reference value <7.6). AMAs remain positive, with mitochondrial pattern. Extractable nuclear antigens, including myopathies-associated antibodies were negative. Her respiratory function, chest x-ray, echocardiogram and electromyogram were normal. Cancer screening was negative. A muscular biopsy was performed and revealed a diffuse mononuclear inflammatory infiltrate (Figure 1) with predominance of CD4+ cells, muscle fibers necrosis (Figure 2), major histocompatibility complex (MHC) – I/II upregulation, rare cytochrome oxidase negative fibers, without perifascicular atrophy or complement deposition, suggestive of inflammatory myositis. When biopsy result was available, she initiates prednisolone 1mg/kg/day with a tapering scheme and methotrexate. Clinical improvement was remarkable. Laboratory findings have a decreasing pattern and consecutive normalization after 4 months of treatment: AST 14U/L, ALT 23U/L, CK 26U/L, LDH 213 U/L and aldolase 4.0 U/L.

PATIENT 2

A male aged 67-years-old presented in the Neurology Department with sensory-motor complaints mainly in

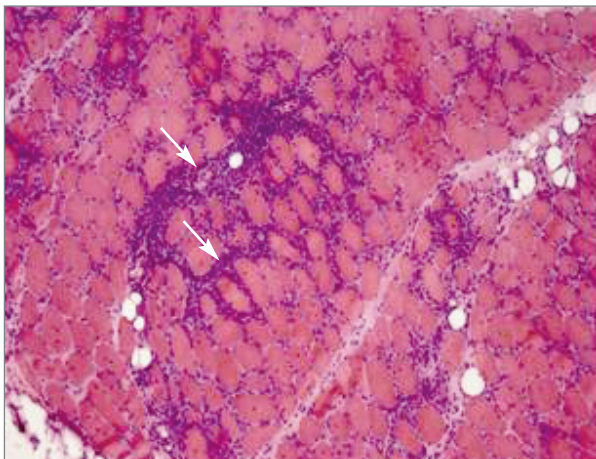


FIGURE 1. Diffuse mononuclear inflammatory infiltrate in the perimysium and endomysium

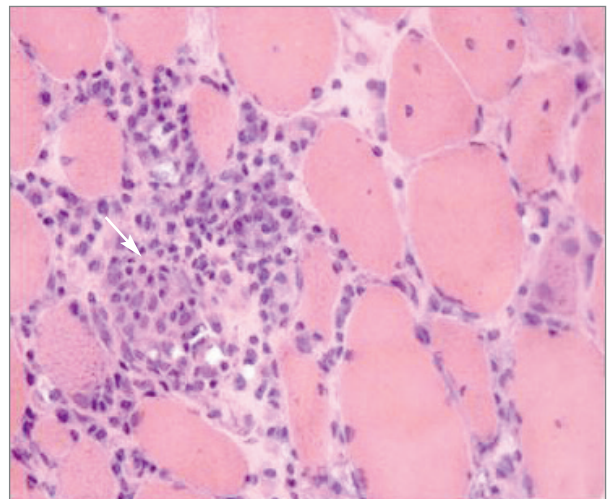


FIGURE 2. Muscle fibers necrosis

his upper arms and gait unbalance, with a progressive course over the previous two months. His neurological examination was remarkable for a tetraparesis with proximal and distal involvement (mainly in his left upper limb – grade 4 in Medical Research Council Muscle Scale), generalized areflexia, algic hypoesthesia in a stock and glove-pattern and a generalized decrease in vibratory sense. His gait was ataxic with a positive Romberg sign. Complementary investigation revealed a demyelinating sensory-motor polyneuropathy in nerve conduction studies and a mild albumin-cytological dissociation in cerebrospinal fluid (69 mg/dL proteins, <2 leucocytes). After a negative investigation for other causes of demyelinating neuropathies (including paraproteinemias, infectious, thyroid and neoplastic diseases) a diagnosis of Chronic Inflammatory Demyelinating neuropathy (CIDP) was made.

The initial symptomatic control of CIDP was not achieved with intravenous immunoglobulin (IvIG), so corticotherapy was started and tapered to a daily dose of prednisolone 60 mg. Even so, several trials of immunomodulatory treatments were needed to achieve symptomatic control (plasma exchange, subcutaneous immunoglobulin, pulses of methylprednisolone) and mycophenolate mofetil 1g twice a day was also added.

Then a progressive 6-month worsening happened when he was 70 - he was unable to walk unaided due to motor and sensory complaints, fatigue and dorsal and lombar pain. His neurological examination revealed a worsening of motor strength, especially on his upper limbs – grade 3 in left proximal upper limb and grade 2 distal in the left upper limb - and of sensory signs. The investigation conducted at that time showed an auto-immune profile compatible with PBC – positive AMAs (titer 160) and anti-Pyruvate Dehydrogenase IgG-M2 (12.0, normal range < 4.0). A retrospective survey of his cholestatic liver enzymes showed a previously unexplained increase in ALP for more than 3 months, with a peak value of 221 U/L (reference 120 U/L) and GGT with a maximum of 248 U/L (reference < 50 U/L). Abdominal ultrasound was normal, without evidence of secondary causes of cholestasis or liver changes.

Dorsal and lumbar MRI revealed lumbar fractures, related to his long-time therapy with corticotherapy. Treatment with ursodesoxycolic-acid was started, and immunomodulation with IvIG was increased. This allowed a better symptomatic control even with a progressive reduction of corticotherapy, both in CIDP symptoms and fatigue management.

DISCUSSION

PBC is a rare and progressive cholestatic liver disease and is frequently associated with other autoimmune disorders. The most frequent ones are Sjögren syndrome, rheumatoid arthritis, systemic sclerosis and sicca syndrome⁷.

Neurologic diseases in patients with PBC have been poorly defined. The association between PBC and inflammatory myopathies and peripheral neuropathies has been reported mainly as case reports. In the available literature, the majority of the case reports was associated with polymyositis and non-inflammatory myopathy⁵⁻¹⁶. Usually, PBC has preceded the diagnosis of myopathy^{12,15-17} or was concomitant^{6,7,9-11} and normally was asymptomatic^{8-11,15,18}.

PBC and myopathy are two diseases with impaired immune function but the precise pathogenesis has not been defined yet. The co-occurrence of both entities suggests the possible existence of shared pathogenic mechanisms between these two pathologies.

It is believed that humoral and cellular immune activation, including antigens of the MHC may play a significant role in this field⁷. Different authors suggest a possible mechanism where AMAs act directly against specific mitochondrial proteins in skeletal muscle, diaphragm and other organs¹⁵.

A Chinese study that evaluated 322 patients with PBC found PBC-Polymyositis coexistence in 3.1%¹⁹. In contrast, another study, with a cohort of 160 patients with PBC, found no reports of polymyositis and the association with neuropathies was not studied².

Maeda *et al.* reviewed 212 patients with myositis and 11.3% had positive AMAs (7 patients with PBC). In 3 of these patients, PBC was diagnosed before the development of inflammatory myopathies and both diagnosis were concomitant in 4 of them⁵. Jemima Albayda *et al.* conduct a retrospective case series review of patients with AMA and PM or DM. They identified 7 patients with AMA-associated myositis of a total of 1180 patients with myositis and only one of these patients had PBC¹³.

Neuropathy associated with PBC is very rare. It has been hypothesized that the association between PBC and CIDP, an immune demyelinating neuropathy, does not happen accidentally. The MHC-II is expressed both in the myelinated fibers in patients with CIDP and in the biliary ducts of patients with PBC, bringing to the discussion that common antigens exist in the biliary epithelial cells and schwann cells. The immune back-

ground of the two diseases may also be the same and related to a deregulation of T helper cell type 17 and T regulatory cell response, that maintain a local microenvironment that perpetuates inflammation¹⁸.

Hendrickse MT and Triger DR evaluated 27 patients with PBC and concluded that those patients had significantly lower nerve conduction velocities and higher vibration thresholds when compared to age matched controls. Of this group, 55.5% of patients had neurophysiological abnormalities and 40.7% had symptoms and/or signs of peripheral neuropathy when stimulated (spontaneous symptoms were rarely seen). The most described symptoms were paresthesia and peripheral numbness. They suggested that generalized neuropathy with peripheral and autonomic abnormalities are common in PBC and could be related to hepatic damage²⁰.

Katalin Keresztes *et al.* analyzed 24 female patients with PBC and found peripheral sensory neuropathy in 54% and lower extremities were the most affected local. They found no correlation between peripheral nerve function and severity of PBC²¹.

There are old references in literature to some cases describing peripheral sensory neuropathy in patients with PBC, mostly due to lipid infiltration of peripheral nerves²⁰. Before 1990 there are descriptions of coexistence of pure sensory neuropathy and PBC. Illa I *et al.* suggested that a possible explanation could be the presence of infiltrates in the dorsal root ganglia²².

This article describes two cases of PBC and neurological manifestations, which are uncommon.

In patient number 1, we report an association between asymptomatic PBC and progressive generalized myalgias with increased serum muscle enzyme levels and a muscular biopsy positive for inflammatory myositis. Differential diagnosis was made with other myopathies that were ruled out by history, physical examination and laboratory results. After treatment, she has progressive clinical improvement.

In patient number 2, we report an association between demyelinating neuropathy and PBC. In this case we admit that fatigue was related to the PBC. Although it is not a specific feature, it clinically responded with therapy for PBC and was not an initial feature when CIDP was first diagnosed. Also, his neurological disease was always of very difficult control, but that is difficult to relate to PBC. We believe that the chronic immunosuppressant therapy might have contributed to the very mild hepatic involvement in PBC.

Although these are rare clinical associations, these

two cases reinforce the importance of the clinician being alert to this possibility. A prompt and correct diagnosis is crucial to the establishment of treatment approach and therefore to a successful outcome.

CORRESPONDENCE TO

Luisa Brites
Praceta Prof Mota Pinto
E-mail: luisapbrites@gmail.com

REFERENCES

1. EASL Clinical Practice Guidelines: The diagnosis and management of patients with primary biliary cholangitis. *J Hepatol.* 2017;67(1):145–172.
2. Watt FE, James OFW, Jones DEJ. Patterns of autoimmunity in primary biliary cirrhosis patients and their families: a population-based cohort study. *QJM.* 2004 Jul;97(7):397–406.
3. Ali AH, Carey EJ, Lindor KD. The management of autoimmunity in patients with cholestatic liver diseases. *Expert Rev Gastroenterol Hepatol.* 2016;10(1):73–91.
4. Boonstra K, Beuers U, Ponsioen CY. Epidemiology of primary sclerosing cholangitis and primary biliary cirrhosis: a systematic review. *J Hepatol.* 2012 May;56(5):1181–1188.
5. Maeda MH, Tsuji S, Shimizu J. Inflammatory myopathies associated with anti-mitochondrial antibodies. *Brain.* 2012 Jun;135(Pt 6):1767–1777.
6. Migueletto BC, Neto AE, Domingues EZ, Neves de Castro PP, Stocker H, Marie SK, *et al.* Primary biliary cirrhosis and myopathy: an uncommon association. *Rev Hosp Clin Fac Med Sao Paulo.* 1999;54(5):165–168.
7. Milosevic M, Adams P. Primary biliary cirrhosis and polymyositis. *J Clin Gastroenterol.* 1990 Jun;12(3):332–335.
8. Harada N, Dohmen K, Itoh H, Ohshima T, Yamamoto H, Naganano M, *et al.* Sibling cases of primary biliary cirrhosis associated with polymyositis, vasculitis and Hashimoto's thyroiditis. *Intern Med.* 1992 Feb;31(2):289–293.
9. Honma F, Shio K, Monoe K, Kanno Y, Takahashi A, Yokokawa J, *et al.* Primary biliary cirrhosis complicated by polymyositis and pulmonary hypertension. *Intern Med.* 2008;47(7):667–669.
10. Demirag MD, Goker B, Haznedaroglu S, Ozturk MA, Karakan T, Kuruoglu R. Osteomalacic myopathy associated with coexisting coeliac disease and primary biliary cirrhosis. *Med Princ Pract.* 2008;17(5):425–428.
11. Boki KA, Dourakis SP. Polymyositis associated with primary biliary cirrhosis. *Clin Rheumatol.* 1995 May;14(3):375–378.
12. Ahn JH, Kim TH, Peck KR, Song YW. A Case of Polymyositis in a Patient with Primary Biliary Cirrhosis Treated with D-Penicillamine. Vol. 8, *The Korean Journal of Internal Medicine.* 1993. p. 46–50.
13. Albayda J, Khan A, Casciola-Rosen L, Corse AM, Paik JJ, Christopher-Stine L. Inflammatory myopathy associated with anti-mitochondrial antibodies: A distinct phenotype with cardiac involvement. *Semin Arthritis Rheum.* 2018 Feb;47(4):552–556.
14. Kurihara Y, Shishido T, Oku K, Takamatsu M, Ishiguro H, Suzuki A, *et al.* Polymyositis associated with autoimmune hepatitis, primary biliary cirrhosis, and autoimmune thrombocytopenic purpura. *Mod Rheumatol.* 2011 Jun;21(3):325–329.
15. Varga J, Heiman-Patterson T, Munoz S, Love LA. Myopathy

- with mitochondrial alterations in patients with primary biliary cirrhosis and antimitochondrial antibodies. *Arthritis Rheum.* 1993 Oct;36(10):1468–1475.
16. Tanaka K, Sato A, Kasuga K, Kanazawa M, Yanagawa K, Umeda M, *et al.* Chronic myositis with cardiomyopathy and respiratory failure associated with mild form of organ-specific autoimmune diseases. *Clin Rheumatol.* 2007 Nov;26(11):1917–1919.
 17. Pamfil C, Candrea E, Berki E, Popov HI, Radu PI, Rednic S. Primary biliary cirrhosis--autoimmune hepatitis overlap syndrome associated with dermatomyositis, autoimmune thyroiditis and antiphospholipid syndrome. *J Gastrointest Liver Dis.* 2015 Mar;24(1):101–104.
 18. Murata K, Ishiguchi H, Ando R, Miwa H, Kondo T. Chronic inflammatory demyelinating polyneuropathy associated with primary biliary cirrhosis. *J Clin Neurosci Off J Neurosurg Soc Australas.* 2013 Dec;20(12):1799–1801.
 19. Wang L, Zhang F-C, Chen H, Zhang X, Xu D, Li Y-Z, *et al.* Connective tissue diseases in primary biliary cirrhosis: A population-based cohort study. Vol. 19, *World Journal of Gastroenterology : WJG.* 2013. p. 5131–5137.
 20. Hendrickse MT, Triger DR. Autonomic and peripheral neuropathy in primary biliary cirrhosis. *J Hepatol.* 1993 Nov;19(3):401–407.
 21. Keresztes K, Istenes I, Folhoffer A, Lakatos PL, Horvath A, Csak T, *et al.* Autonomic and sensory nerve dysfunction in primary biliary cirrhosis. Vol. 10, *World Journal of Gastroenterology : WJG.* 2004. p. 3039–43.
 22. Illa I, Graus F, Ferrer I, Enriquez J. Sensory neuropathy as the initial manifestation of primary biliary cirrhosis. Vol. 52, *Journal of Neurology, Neurosurgery, and Psychiatry.* 1989. p. 1307.